

Subcutaneous curettage vs. injection of botulinum toxin A for treatment of axillary hyperhidrosis

R Rompel,* S Scholz

Department of Dermatology, Klinikum Kassel, Münchebergstr. 41–43, D-34125 Kassel, Germany. *Corresponding author, tel. +49 561 980 3308; fax +49 561 980 6976; E-mail: rompel@klinikum-kassel.de

ABSTRACT

Background Axillary hyperhidrosis is a functional non-inflammatory abnormality of the eccrine sweat glands. The cause of genuine hyperhidrosis is unknown and, therefore, no specific corrective therapy is available and conservative treatment often fails. Subcutaneous sweat gland curettage of the axillae is one of the proven surgical modalities. Local injection of botulinum toxin A (BT-A) is a promising new conservative approach.

Objective The purpose of this study was to compare the efficacy of subcutaneous curettage vs. injection of BT-A in axillary hyperhidrosis.

Methods A total of 113 patients (36.3% males, 63.7% females) suffering from genuine axillary hyperhidrosis were treated by either subcutaneous curettage ($n = 90$) or local injection of BT-A ($n = 23$). Median follow-up period was 23.5 months. Questionnaires were handed out to patients for a subjective assessment of symptoms before treatment, 6 months after the procedure, and at the time of last follow-up. The patients were asked to rate the amount of axillary sweating based on a score ranging from 1 (no axillary secretion) to 6 (maximum axillary secretion). The subjective scores of sweating at rest, at high temperatures, under physical stress, under emotional stress and after spicy meals were assessed.

Results The patients' subjective assessments of the overall outcome after subcutaneous curettage were 'very good' in 36.4%, 'good' in 29.9% and 'satisfactory' in 16.9%. The subjective score of axillary sweating at rest was reduced to 40.0% after 6 months, and finally to 45.7% at the end of follow-up (median: 28.2 months). Patients treated by BT-A injection assessed outcome as 'very good' in 39.1%, 'good' in 21.7% and 'satisfactory' in 8.7%. Sweating at rest was reduced to 48.5% after 6 months, and finally to 68.8% at the end of follow-up (median: 16.1 months). The mean duration of the antiperspiration effect of BT-A was 7.6 months (median: 7 months), but there were two cases of long durations, i.e. 14 and 18 months.

Conclusions Subcutaneous curettage and injection of BT-A both present major advantages compared with earlier methods. Subcutaneous curettage offers the same permanent efficacy but far fewer side-effects than sympathectomy, and less scarring than local excisional procedures, respectively. Of the conservative approaches BT-A is by far the most efficacious. Patients should be informed of the advantages and disadvantages of both methods.

Key words: axillary hyperhidrosis, botulinum toxin A, subcutaneous curettage

Received: 6 April 2000, accepted 30 January 2001

Introduction

Axillary hyperhidrosis is a functional non-inflammatory abnormality of the eccrine sweat glands. Afflicted subjects usually experience severe discomfort and sometimes even social stigmatization.^{1–3} The extreme sweat production, even at times

of rest, is very distressing for the individual, causing obvious social problems, and clothes may be damaged and various occupations become impossible. The cause of genuine hyperhidrosis is unknown and, therefore, no specific corrective therapy is available and conservative treatment often fails.^{4–6} Local antiperspirants, aluminium salts and astringents act for a

very short time and the use of iontophoresis is limited because of anatomical reasons. Local radiation, formerly described, is obsolete.⁵

Of the surgical modalities, open or endoscopic sympathectomy bears a relatively high risk of untoward complications.⁷⁻¹⁰ Therefore, local surgical methods are preferable in axillary hyperhidrosis. Various local surgical methods described for axillary hyperhidrosis can be divided into three major approaches: (i) removing only subcutaneous tissue without removing skin;¹¹⁻¹⁸ (ii) removing skin and subcutaneous tissue by wide excision;¹⁹⁻²⁴ and (iii) partial excision of the skin and subcutaneous tissue as well as open curettage of the adjacent area.²⁵⁻²⁹ We prefer the technique first described by Jemec in 1975 involving removal of subcutaneous tissue of the axilla by means of curettage.^{13,30}

Botulinum toxin A (BT-A) injection is a promising new therapeutic option for hyperhidrosis with minimal adverse reactions and high efficacy.³¹⁻³⁵ However, the duration of the effect of BT-A is limited to about 6-12 months.³⁶⁻⁴⁰

We report on the results of subcutaneous curettage compared with local injection of BT-A for the treatment of axillary hyperhidrosis.

Patients and methods

Patients

At the Department of Dermatology, Kassel, Germany, during 1993-99, 113 patients (36.3% males, 63.7% females) suffering from genuine axillary hyperhidrosis were treated with subcutaneous curettage ($n = 90$) or local injection of BT-A ($n = 23$). The mean age of the patients was 30.9 years (median: 30 years). All patients had severe axillary hyperhidrosis, confirmed using the iodine starch test, and fulfilling the following criteria: (i) local and systemic drug therapy had failed to improve their symptoms, and (ii) the patients were severely disabled in regard to their occupation and social activities. Long-term follow-up by questionnaire and/or clinical examination was completed in 88.5% of the patients.

Complete follow-up was achieved in 77 cases of subcutaneous curettage (85.6%), and 23 after BT-A treatment (100%). The median follow-up period was 23.5 months. Postoperative follow-up was not achieved in 13 cases because they lived too far from Kassel or they had moved without leaving a forwarding address. At re-examination local control of scars and arm motility was performed. The patients underwent a second sweat test to confirm the reduction of hyperhidrosis. Patient questionnaires were distributed for subjective assessment of symptoms: before treatment, 6 months after the procedure and at the time of the last follow-up. The patients were asked to record the amount of axillary sweating based on a score ranging from 1 (no axillary secretion) to 6 (maximum axillary secretion). The subjective scores of sweating at rest, at high temperatures, under

physical stress, under emotional stress and after spicy meals were assessed. In addition, the patients were asked if they were satisfied with the overall result of the procedure, if they would undergo the procedure again and if they would recommend the procedure to others.

Subcutaneous curettage

Prior to the operation, the iodine starch test was performed in order to delineate the zone of maximum sweating in the axillary region. The indicated area was outlined with a water-resistant skin marker and surgery was carried out under general anaesthesia in all patients.

During the operation, the patient is placed in a supine position with the arms abducted 90°. A 2-3-cm incision is made caudal to the posterior pole of the marked zone. Metzenbaum scissors are used to undermine the entire marked area of hyperhidrosis. Then, the undermined area is curetted using a sharp curette, like that used in gynaecology. Both the superficial and deep surfaces are scraped to remove the sweat glands and inevitably other tissue. We insert a size 12-14 CH suction drain and then close the wound with subcutaneous and skin sutures. The postoperative dressings should apply soft pressure to minimize haematoma formation. The suction drain is removed after secretion has decreased to less than 10 mL/d, usually on the third or fourth day. The sutures are removed at about the tenth day.

Injection of botulinum toxin A

As above before surgery, prior to the injection, the iodine starch test was performed in order to outline the area of maximum sweating. One ampoule of Botox™ (100 units) respectively Dysport™ (500 units) was diluted with 5 mL of non-conserved sterile physiologic saline solution, resulting in a concentration of 2 units per 0.1 mL solution Botox™, and 10 units per 0.1 mL solution Dysport™, respectively (1 unit of Botox™ refers to 5 units of Dysport™). Using a small 26-gauge needle 2-2.5 mL = 40-50 units of Botox™ (2-2.5 mL = 200-250 units of Dysport™) were administered by 20-25 intradermal injections into the area of each axilla. Fourteen patients received Botox™ and nine patients received Dysport™.

Results

The overall complication rate after subcutaneous curettage was 17.8% (Table 1). These included minor complications such as wound infection and partial epidermal necrosis, which healed with appropriate treatment. Haematoma formation in 12 patients required surgical revision and additional suction drainage. In all cases of complications, healing ad integrum was achieved. There were no adverse reactions after treatment with BT-A except for minimal superficial haematoma, with spontaneous resolution in a few days (Table 1).

Table 1 Complications after treatment of axillary hyperhidrosis

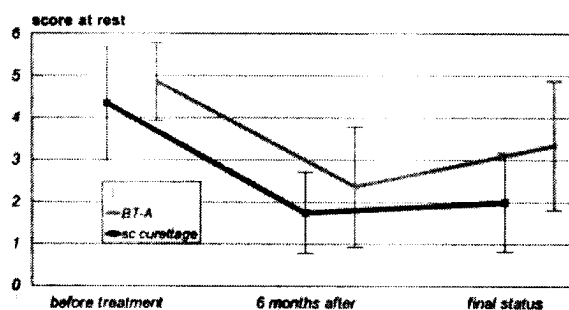
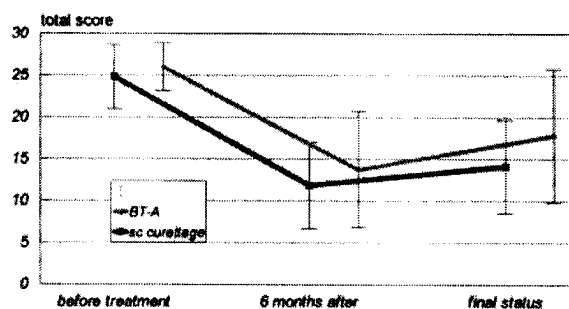
Complications	Subcutaneous curettage (n = 90) n (%)	BT-A injection (n = 23) n (%)
Partial epidermal necrosis	2 (2.2)	0
Wound infection	2 (2.2)	0
Bleeding/haematoma	12 (13.3)	0
Others	0	0

Table 2 Results of treatment of axillary hyperhidrosis (all patients with complete follow-up)

Subjective results	Subcutaneous curettage (n = 77) n (%)	BT-A injection (n = 23) n (%)	χ^2 -test P
General satisfaction with the procedure			
very good	28 (36.4)	9 (39.1)	NS
good	23 (29.9)	5 (21.7)	
satisfied	13 (19.9)	2 (8.7)	
dissatisfied	12 (15.6)	7 (30.4)	
no answer	1 (1.3)		
Would you recommend the procedure to other patients?			
yes	70 (90.9)	22 (95.7)	NS
no	6 (7.8)	1 (4.3)	
no answer	1 (1.3)		
Judgement of the surgical scar			
minimally visible	52 (67.5)	-	-
markedly visible	21 (27.3)	-	
bothersome	3 (3.9)	-	
no answer	1 (1.3)	-	

NS, not significant

The patients' subjective assessment (Table 2) of final outcome after subcutaneous curettage was 'very good' in 36.4%, 'good' in 29.9% and 'satisfactory' in 16.9% of cases; 15.6% of the patients were not satisfied with the result. The subjective score of axillary sweating at rest was reduced to 40.0% after 6 months, and finally to 45.7% at the end of follow-up (median: 28.2 months) (fig. 1). The overall subjective score (sweating at rest, physical stress, heat, psychic stress, hot spices) was reduced to 48.2% after 6 months and finally to 56.9% compared with the initial score (100%) (fig. 2). The surgical scar was minimally visible in 65.5% of the subjects treated with subcutaneous curettage.

**fig. 1** Patients' subjective scores by questionnaire (vertical axis) of sweating at rest before treatment, 6 months after the procedure and at final assessment, respectively. Comparison of mean \pm SD of treatment by subcutaneous curettage (n = 77) vs. botulinum toxin A (n = 23).**fig. 2** Patients' subjective total scores by questionnaire (vertical axis) before treatment, 6 months after the procedure, and at final assessment, respectively. Comparison of mean \pm SD of treatment by subcutaneous curettage (n = 77) vs. botulinum toxin A (n = 23).

Patients treated with an injection of BT-A assessed a result of 'very good' in 39.1%, 'good' in 21.7% and 'satisfactory' in 8.7% of cases; 30.4% of the patients were not satisfied (Table 2). Sweating at rest was reduced to 48.5% after 6 months, and finally to 68.8% at the end of follow-up (median: 16.1 months) (fig. 1). The overall subjective score was reduced to 52.8% after 6 months and finally to 68.6% as compared with the initial score (fig. 2); 90.9% of the surgically treated subjects and 95.7% of the BT-A groups would recommend the procedure to others. The reported mean duration of the antiperspiration effect of BT-A was 7.6 months (median: 7 months, there was no significant difference between Botox™ and Dysport™ concerning duration of the effect), with two cases of especially long duration, i.e. 14 and 18 months (fig. 3).

Discussion

Axillary hyperhidrosis is a relatively common problem with a prevalence of about 0.6–1.0%, mainly affecting young adults without predilection of race or gender.^{2,3} A positive family history has been reported in 45–90% of cases;^{3,19} in our case series it was 37.2%. This would be consistent with an autosomal dominant transmission. Excessive sweating is often present at

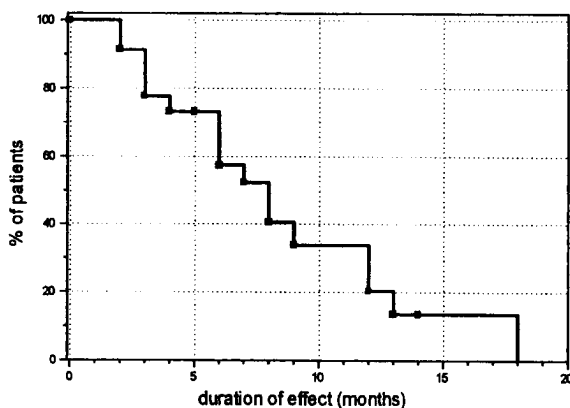


fig. 3 Time-event analysis of the duration of the antiperspiration effect of botulinum toxin A.

rest and may be further provoked by emotional and thermal stimuli or physical stress. Bromhidrosis is less likely due to the large amount of axillary perspiration that flushes away apocrine secretion and bacterial colonization.¹² However, social stigmatization and secondary emotional and psychic problems are common.

Subjects usually have a history of various unsuccessful treatments, including local antiperspiration agents, iontophoresis and systemic agents.^{1,5,41} Various types of surgical procedures have been developed for the treatment of axillary hyperhidrosis. As sympathectomy bears the risk of severe complications and side-effects, such as compensatory hyperhidrosis, pneumothorax, Horner's syndrome, etc.,⁷⁻¹⁰ local surgical approaches are currently preferred.^{11,17,42} The axillary sweat glands in the axilla consist of apocrine and eccrine glands and their distribution is closely related to the hair-bearing area.^{1,2} The aim of local surgery is to reduce the amount of eccrine and also apocrine glands, which leads to both subjective and objective improvement. Many recommended local operations for hyperhidrosis have been described in the literature. Subcutaneous resections can be done by curettage^{13,19,30} or liposuction.^{11,16,18} Open curettage with partial excision or CO₂ laser vaporization are modifications of this approach.^{15,17,28} Wide excisions with primary suture or plastic repair are limited because of the risk of contractures, scars and bleeding.^{21,23,24} Of the surgical methods, we prefer subcutaneous curettage due to its high efficacy and the absence of systemic complications, common following sympathectomy, although local complications are not uncommon but can be managed and healed ad integrum. Axillary liposuction for hyperhidrosis appears to be comparable with our method in efficacy, but there are few long-term experiences.^{11,16,18} Our results show that good long-term results can be achieved with a reduction of axillary sweating at rest and with physical stress, as shown by the patients' subjective assessment scores; 86.2% of all patients were satisfied with the result of the operation. The advantage of subcutaneous curettage is that it can be repeated, if necessary, and other methods, such

as partial excision can be done subsequently.³⁰ The technique leaves minimal scar formation in the axillary region, and no contractures that may lead to impairment of shoulder-arm mobility were seen.^{14,30}

Treatment with BT-A is well established for neurological disorders, such as blepharospasm, hemifacial spasm and torticollis.^{34,39} The toxin blocks cholinergic sympathetic innervation of the sweat glands by specific inhibition of acetylcholine-dependent neuroglandular transmission (= chemodenervation).^{33,34,39} Recent studies have confirmed its safety and efficacy in palmar, axillary and gustatory hyperhidrosis.^{36,37,43} However, the duration of the effect is only about 6-12 months.^{38,40} Our results revealed a good response of hyperhidrosis to BT-A with sweat reduction, after 6 months, at rest up to 48.5% and a total score after 6 months reduced to 52.8%. However, final scores at the time of the last follow-up were markedly higher, indicating the limited duration of the effect. None of our patients experienced any adverse reactions following injection of BT-A at the above-mentioned doses. Thus, intracutaneous injections of botulinum toxin offer a simple, safe, effective alternative to other conservative and surgical options, although the duration of the effect is limited.

Subcutaneous curettage and injection of botulinum toxin both have major advantages compared with earlier methods. Subcutaneous curettage offers the same permanent efficacy, but far fewer side-effects than sympathectomy, and less scarring than local excisional procedures, respectively. Of the non-surgical approaches, botulinum toxin represents by far the most efficacious compared with local antiperspirants, iontophoresis or systemic drugs. However, the therapeutic effect is limited in time, and today no long-term experience is available on how many treatments of botulinum toxin a patient can tolerate. Patients with axillary hyperhidrosis should be informed of the advantages and disadvantages of both methods.

References

- 1 Frewin DB, Downey JA. Sweating-physiology and pathophysiology. *Australas J Dermatol* 1976; 17: 82-86.
- 2 Hölzle E. Pathophysiologische Aspekte und klinische Erscheinungsbilder der Hyperhidrosis. *Hautarzt* 1983; 34: 596-604.
- 3 Hurley HJ, Shelley WB. Axillary hyperhidrosis: clinical features and local surgical management. *Br J Dermatol* 1966; 78: 127-132.
- 4 Bergkvist L, Engevik L. The surgical treatment of axillary hyperhidrosis. *Br J Surg* 1979; 66: 482-484.
- 5 Hölzle E. Therapie der Hyperhidrosis. *Hautarzt* 1984; 35: 7-15.
- 6 Sabatier H, Picaud AJ. The surgical treatment of axillary hyperhidrosis. *J Dermatol Surg* 1976; 2: 331-332.
- 7 Drott C, Gothberg G, Claes G. Endoscopic transthoracic sympathectomy: an efficient and safe method for the treatment of hyperhidrosis. *J Am Acad Dermatol* 1995; 33: 78-81.
- 8 Herbst F, Plas EG, Fugger R, Fritsch A. Endoscopic thoracic sympathectomy for primary hyperhidrosis of the upper limbs. A

- critical analysis and long-term results of 480 operations. *Ann Surg* 1994; 220: 86–90.
- 9 Rex LO, Drott C, Claes G *et al.* The Boras experience of endoscopic thoracic sympathectomy for palmar, axillary, facial hyperhidrosis and facial blushing. *Eur J Surg Suppl* 1998; 580: 23–26.
 - 10 Zacherl J, Huber ER, Imhof M *et al.* Long-term results of 630 thoracoscopic sympathectomies for primary hyperhidrosis: the Vienna experience. *Eur J Surg Suppl* 1998; 580: 43–46.
 - 11 Hasche E, Hagedorn M, Sattler G. Die subkutane Schweißdrüsen-saugkürettage in Tumescenzlokalanästhesie bei Hyperhidrosis axillaris. *Hautarzt* 1997; 48: 817–819.
 - 12 Inaba M, Anthony J, Ezaki T. Radical operation to stop axillary odor and hyperhidrosis. *Plast Reconstr Surg* 1978; 62: 355–360.
 - 13 Jemec B. Abrasio axillae in hyperhidrosis. *Scand J Plast Reconstr Surg* 1975; 9: 44–46.
 - 14 Jemec B, Holm Hansen B. Follow-up of patients operated on for axillary hyperhidrosis by subcutaneous curettage. *Scand J Plast Reconstr Surg* 1978; 12: 65–67.
 - 15 Landes E, Kappesser HJ. Zur operativen Behandlung der Hyperhidrosis axillaris. *Fortschr Med* 1979; 97: 2169–2171.
 - 16 Lillis PJ, Coleman WP, 3d. Liposuction for treatment of axillary hyperhidrosis. *Dermatol Clin* 1990; 8: 479–482.
 - 17 Park DH, Kim TM, Han DG, Ahn KY. A comparative study of the surgical treatment of axillary osmidrosis by instrument, manual, and combined subcutaneous shaving procedures. *Ann Plast Surg* 1998; 41: 488–497.
 - 18 Payne CM, Doe PT. Liposuction for axillary hyperhidrosis. *Clin Exp Dermatol* 1998; 23: 9–10.
 - 19 Bretteville-Jensen G. Radical sweat gland ablation for axillary hyperhidrosis. *Br J Plast Surg* 1973; 26: 158–162.
 - 20 Eldh J, Fogdestam I. Surgical treatment of hyperhidrosis axillae. *Scand J Plast Reconstr Surg* 1976; 10: 227–229.
 - 21 Hartmann M, Petres J. Operative Therapie der Hyperhidrosis axillaris. *Hautarzt* 1978; 29: 82–85.
 - 22 Hurley HJ, Shelley WB. A simple surgical approach to the management of axillary hyperhidrosis. *JAMA* 1963; 186: 109–115.
 - 23 Skoog T, Thyresson N. Hyperhidrosis of the axillae: a method of surgical treatment. *Acta Chir Scand* 1962; 124: 531–538.
 - 24 Wang HJ, Cheng TY, Chen TM. Surgical management of axillary bromidrosis – a modified Skoog procedure by an axillary bipedicle flap approach. *Plast Reconstr Surg* 1996; 98: 524–529.
 - 25 Bisbal J, del Cacho C, Casalots J. Surgical treatment of axillary hyperhidrosis. *Ann Plast Surg* 1987; 18: 429–436.
 - 26 Endo T, Nakayama Y. Surgical treatment of axillary osmidrosis. *Ann Plast Surg* 1993; 30: 136–139.
 - 27 Gillespie JA, Kane SP. Evaluation of a simple surgical treatment of axillary hyperhidrosis. *Br J Dermatol* 1970; 83: 684–689.
 - 28 Park JH, Cha SH, Park SD. Carbon dioxide laser treatment vs. subcutaneous resection of axillary osmidrosis. *Dermatol Surg* 1997; 23: 247–251.
 - 29 Wu WH, Ma S, Lin JT *et al.* Surgical treatment of axillary osmidrosis: an analysis of 343 cases. *Plast Reconstr Surg* 1994; 94: 288–294.
 - 30 Rompel R, Peros I, Petres J. Subcutaneous curettage for the treatment of axillary hyperhidrosis. *Eur J Dermatol* 1997; 7: 43–46.
 - 31 Bushara KO, Park DM, Jones JC, Schutta HS. Botulinum toxin – a possible new treatment for axillary hyperhidrosis. *Clin Exp Dermatol* 1996; 21: 276–278.
 - 32 Drobik C, Laskawi R, Schwab S. Die Therapie des Frey-Syndroms mit Botulinumtoxin A. Erfahrungen mit einer neuen Behandlungsmethode. *HNO* 1995; 43: 644–648.
 - 33 Grazer FM. A noninvasive surgical treatment of axillary hyperhidrosis. *Clin Dermatol* 1992; 10: 357–364.
 - 34 Heckmann M, Ceballos-Baumann A, Schaller M, Plewig G. Botulinum-toxin A in der Dermatologie. *Hautarzt* 1998; 49: 87–90.
 - 35 Odderson IR. Hyperhidrosis treated by botulinum A exotoxin. *Dermatol Surg* 1998; 24: 1237–1241.
 - 36 Glogau RG. Botulinum A neurotoxin for axillary hyperhidrosis. No sweat Botox. *Dermatol Surg* 1998; 24: 817–819.
 - 37 Heckmann M, Breit S, Ceballos-Baumann A *et al.* Axilläre Hyperhidrose: Erfolgreiche Behandlung mit Botulinumtoxin-A. *Hautarzt* 1998; 49: 87–90.
 - 38 Naumann M, Hofmann U, Bergmann I *et al.* Focal hyperhidrosis: effective treatment with intracutaneous botulinum toxin. *Arch Dermatol* 1998; 134: 301–304.
 - 39 Naumann M, Zellner M, Toyka KV, Reiners K. Treatment of gustatory sweating with botulinum toxin. *Ann Neurol* 1997; 42: 973–975.
 - 40 Schnider P, Binder M, Auff E *et al.* Double-blind trial of botulinum A toxin for the treatment of focal hyperhidrosis of the palms. *Br J Dermatol* 1997; 136: 548–552.
 - 41 Benohanian A, Dansereau A, Bolduc C, Bloom E. Localized hyperhidrosis treated with aluminum chloride in a salicylic acid gel base. *Int J Dermatol* 1998; 37: 701–703.
 - 42 Moran KT, Brady MP. Surgical management of primary hyperhidrosis. *Br J Surg* 1991; 78: 279–283.
 - 43 Shelley WB, Talanin NY, Shelley ED. botulinum toxin therapy for palmar hyperhidrosis. *J Am Acad Dermatol* 1998; 38: 227–229.