

Focal Hyperhidrosis

Effective Treatment With Intracutaneous Botulinum Toxin

Markus Naumann, MD; Uta Hofmann, MD; Ilka Bergmann, MD;
Henning Hamm, MD; Klaus V. Toyka, MD; Karlheinz Reiners, MD

Objective: To evaluate the effect of intracutaneous injections of botulinum toxin type A on excessive focal hyperhidrosis.

Design: Therapeutic before-and-after trial over 4 months.

Setting: Neurological and dermatological university departments.

Patients: Eleven patients with excessive axillary, palmar, or plantar hyperhidrosis fulfilling the following criteria: (1) local and systemic drug therapy had failed to improve their symptoms; (2) the patients were severely disabled with respect to their occupation and social activities; and (3) a successful treatment by botulinum toxin would obviate the need for destructive surgical procedures.

Interventions: Three mouse units of botulinum toxin (Botox) per 4-cm² skin area was injected intracutane-

ously in 16 axillae, 8 palms, and 2 soles.

Main Outcome Measures: Reduction of hyperhidrosis as documented by the Minor iodine-starch test and gravimetric assessment of local spontaneous sweat production measured over 1 minute.

Results: In all patients, botulinum toxin completely abolished sweating in the injected areas ($P < .001$) within 3 to 7 days. No relevant adverse effects occurred and no clinical recurrence of hyperhidrosis was observed within the follow-up period of up to 5 months. Occasionally, subclinical reactivation of sweat gland function was observed 4 months after treatment.

Conclusions: Intracutaneous botulinum toxin seems preferable to any hitherto used conservative or surgical procedures and may become the therapy of choice in pathological focal hyperhidrosis.

Arch Dermatol. 1998;134:301-304

LOCALIZED idiopathic hyperhidrosis is a common disorder of sweating. The pathogenesis is unknown. The preferred sites of sweating are at the axillae, palms, and soles. In excessive cases, sweat runs down the trunk or drips from the hands and feet, a condition that is usually regarded as unacceptable in professional and private life. Profuse sweating leads to skin maceration, which may cause secondary infections.

Treatments include systemic anticholinergic drug therapy; topical application of acids, aldehydes, and metal salts, eg, aluminium chloride; and iontophoresis. If these measures prove ineffective, invasive or surgical treatments, such as sympathetic blockade, transthoracic sympathectomy, and excision or curettage of the most active sweating areas, are current alternatives. However, sweating tends

to return some years after sympathectomy,¹ and the procedure may be complicated by pneumothorax and severe compensatory hyperhidrosis in other parts of the body.² Surgery of the axillary vault may produce excessive scar formation and focal paresthesias or anesthesia.

Botulinum toxin is a potent neurotoxin that blocks cholinergic nerve terminals.³ Earlier studies have shown its effect in reducing sweat production in normal volunteers.^{4,5} After our successful botulinum toxin treatment of excessive palmar hyperhidrosis in a single patient,⁶ we studied the therapeutic effects of botulinum toxin in patients with various types of focal sweating.

RESULTS

Intracutaneous injections of botulinum toxin abolished clinically disturbing hyperhidrosis in all patients. The treatment

From the Departments of Neurology (Drs Naumann, Toyka, and Reiners) and Dermatology (Drs Hofmann, Bergmann, and Hamm), Bayerische Julius-Maximilians-Universität, Würzburg, Germany.

PATIENTS AND METHODS

We treated 11 adult patients (10 women and 1 man; mean±SD age, 30.5±9.0 years) with pathological focal hyperhidrosis that was unresponsive to any prior topical or systemic drug therapy. The duration of hyperhidrosis was 10.8±6.0 (mean±SD) years. The hyperhidrosis was axillary alone in 7 patients, palmar alone in 2 patients, axillary and palmar in 1 patient, and palmar and plantar in 1 patient. All patients were severely disabled by occupational or social consequences of excessive sweating. In total, 16 axillae, 8 palms, and 2 soles were treated. A trial with botulinum toxin was offered before invasive procedures were performed. The results of neurological and dermatological examinations of all patients were unremarkable except for focal hyperhidrosis. The patients were instructed about the procedure and gave their written informed consent.

Before and 2, 4, 12, 16, and 20 weeks after the botulinum toxin injections, the area of hyperhidrosis was visualized by the Minor iodine-starch test (Figure 1). In this test, an iodine solution (2 g of iodine in 10 mL of castor oil and alcohol to 100 mL) is painted over the area of skin to be tested. After it has dried, fine rice or potato starch powder is applied. Sweat causes the mixture to turn dark blue.⁷

Also, in 10 patients, the hyperhidrosis was quantified gravimetrically before and 2 weeks after the botulinum toxin injections by measurement of spontaneous sweat secretion according to the protocol of Reinauer et al.⁸ Briefly, the respective hyperhidrotic area was blotted dry and then brought into contact with copy paper (Xerox) for 1 minute. The amount of sweat secreted during this collection period was then determined as weight increase.

The identified hyperhidrotic area was marked with a pen and subdivided into squares of 2×2 cm² (4 cm²) each. Lyophilized botulinum toxin, type A (Botox, Allergan, Irvine, Calif; 100 mouse units [MU]), was diluted in 5 mL of sterile 0.9% saline. Portions of 0.15 mL (3 MU) were distributed intracutaneously over the area of 4 cm² from a single insertion.

To screen for morphological alterations, a small axillary skin biopsy was performed in 1 patient before and 8 weeks after the botulinum toxin injection. Hematoxylin-eosin staining was used to assess the morphological appearance of the sweat glands, and an immunocytochemical study using an antibody to protein gene product 9.5 (PGP9.5), a pan-axonal marker, was performed to visualize sweat gland innervation.

success was documented by the Minor test and quantitatively by measurement of spontaneous sweat secretion. In 1 patient, axillary reinjection of botulinum toxin was necessary after 2 weeks because of a small, persistent area of sweating. The mean±SD dosage for axillary sweating was 35±8 MU (range, 20-52 MU) of botulinum toxin per side; for palmar sweating, it was 36±7 MU (range, 28-46 MU) per side; and for plantar sweating, it was 42 and 48 MU. The beginning of the botulinum toxin

action was noticed by the patients 2.8±0.7 days (mean±SD) (range, 2-4 days) after injection. Sweating completely stopped 5.2±1.4 days (range, 3-7 days) after injection. The area of hyperhidrosis documented by the Minor test decreased from 46.4±9.8 cm² (mean±SD) before treatment to greatly reduced or no visible sweating 2 weeks after injection (Figure 1, B and D). Quantitatively, sweating significantly declined from 104±38 mg/min (mean±SD) before the botulinum toxin injection to 16±15 mg/min 2 weeks after the injection ($P<.001$, paired *t* test) (Figure 2). There was no evidence of compensatory hyperhidrosis in other areas after treatment. Despite a clear reduction of the hyperhidrosis, the patients with axillary hyperhidrosis did not notice a significant improvement of unpleasant odor after treatment.

Injection of botulinum toxin was well tolerated in the majority of patients, and there were few adverse effects (those that did occur were mild). Injection was moderately painful in the axillary area in 4 of 16 patients and in the palmar area in 6 of 8 patients. After injection, small, painless hematomas were seen in the axillary area in 3 of 16 patients, in the palmar area in 2 of 8 patients, and in the plantar area in 1 patient. No clinical decrease of hand grip force or other hand muscle weakness was observed after palmar injections. No gait impairment occurred with plantar injections. Within the follow-up period of up to 20 weeks (range, 12-20 weeks), no clinical hyperhidrosis could be discovered in 8 of 11 patients. However, 16 weeks after injection, small areas of clinically inapparent restored axillary sweating were observed with the Minor test in 3 patients, all of whom were successfully reinjected 4 weeks later.

Histological examination of an axillary skin biopsy specimen before and 2 months after botulinum toxin treatment revealed no major differences in the morphological features of the sweat glands as seen on hematoxylin-eosin stains (not shown) and no alterations in the sweat gland innervation on protein gene product 9.5 immunohistochemical studies (Figure 1, E and F).

COMMENT

Intracutaneous injection of botulinum toxin was highly effective in abolishing focal hyperhidrosis. Except for a few self-experiments in volunteers^{4,5} and a recent case report from this group,⁶ to our knowledge there are no reports in the literature on the efficacy of botulinum toxin injections on various excessive focal sweating disorders, such as axillary, palmar, or plantar hyperhidrosis.

Long-term studies of disorders with muscular hyperactivity, such as dystonia or spasticity, indicate that the duration of botulinum toxin action at the neuromuscular junction is about 3 months on average.⁹ Botulinum toxin applied to sweat glands appears to have a longer-lasting clinical effect. In gustatory sweating, which frequently occurs after posttraumatic misdirection of the regenerating parasympathetic fibers to the sweat glands, botulinum toxin treatment abolished sweating for more than 12 months.¹⁰ This finding is in agreement with our experience in a large group of patients with gustatory sweating in whom a single injection had an anhidrotic effect that lasted at least 6 months.¹¹ In the present study,

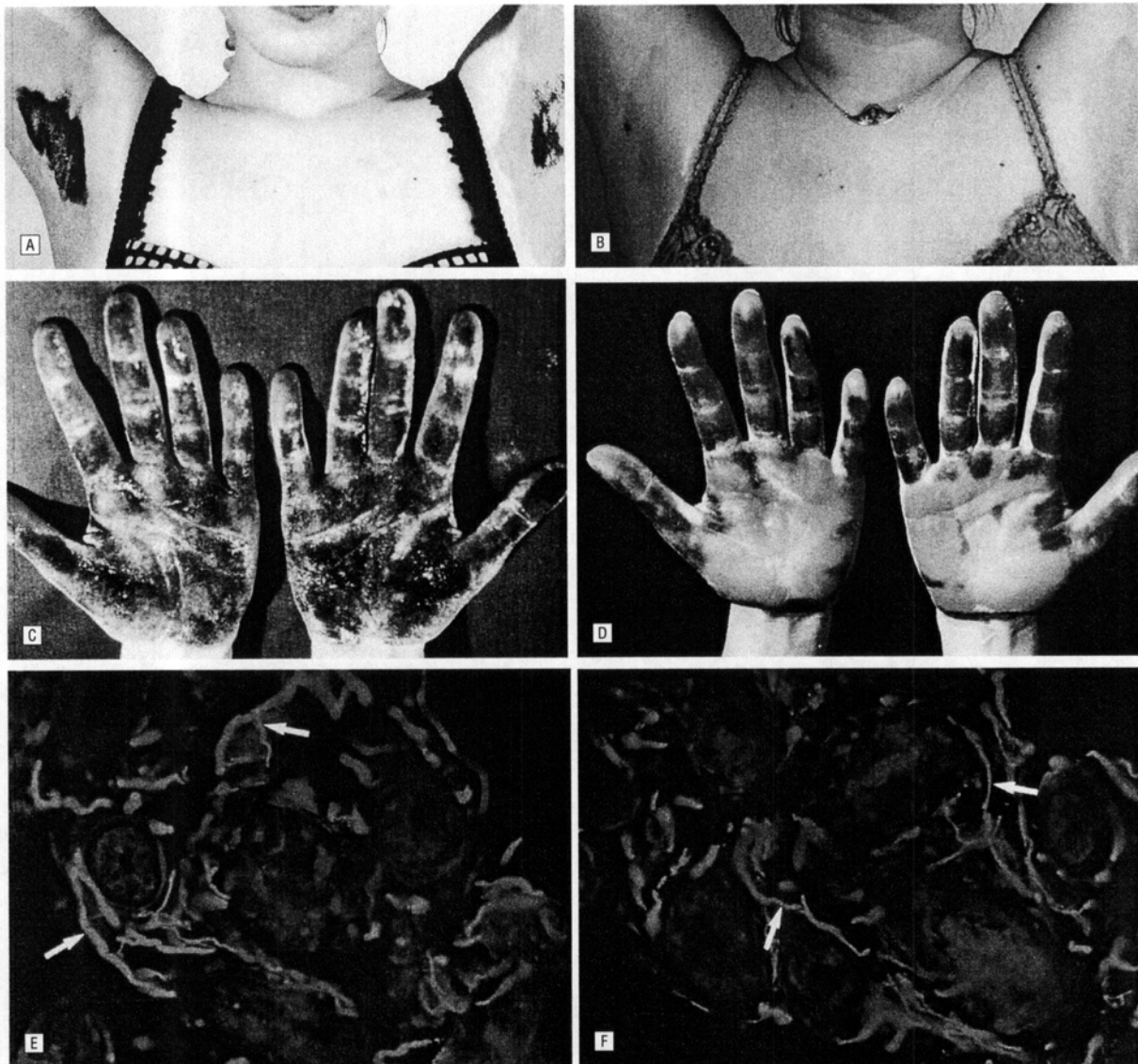


Figure 1. Axillary hyperhidrosis before botulinum toxin injection documented by the Minor iodine-starch test. A, No visible sweating after treatment. B, Palmar hyperhidrosis before (C) and after treatment (D). No major differences in nerve fiber ramification can be seen after treatment (F) compared with before treatment. E, Panaxonal marker protein gene product 9.5. Nerve fibers are indicated by arrows in parts E and F.

no clinical recurrence was observed within 16 weeks after injection, although at that time a clinically inapparent slight sweat production could be visualized by the Minor test in 3 patients, all of whom were reinjected 20 weeks after the first treatment.

At present, it is unclear why the action of botulinum toxin in the autonomic synapses of sweat glands lasts much longer than in the neuromuscular synapses. There are 2 mechanisms limiting the duration of synaptic action of botulinum toxin. First, botulinum toxin type A acts by cleaving a protein (SNAP-25) involved in the fusion of acetylcholine-containing vesicles with the plasma membrane.¹² The rate of resynthesis of SNAP-25 could be higher in neuromuscular synapses than in cholinergic sympathetic nerve endings. Second, at the neuromuscular junction, botulinum toxin application is followed by axonal sprouting and consecutive reinnervation of

muscle fibers.¹³ To date, it is unknown whether sprouting also occurs in sympathetic nerve endings after the administration of botulinum toxin. Longer denervation effects are also seen when botulinum toxin is injected into partially reinnervated tissue, as in gustatory sweating or hemifacial spasm. There is, however, no evidence for a preexisting denervation or reinnervation of sweat glands in idiopathic hyperhidrosis.

While the action of botulinum toxin on motor nerve terminals, with subsequent atrophy of muscle fibers, has been investigated extensively, little is known about the effect of botulinum toxin on autonomic nerve fibers and their end organs.¹³ Based on our histological findings, nerve fiber degeneration and sweat gland atrophy do not appear to be major components of botulinum toxin action. Even in hereditary autonomic neuropathy with anhidrosis, the morphological appearance of sweat glands

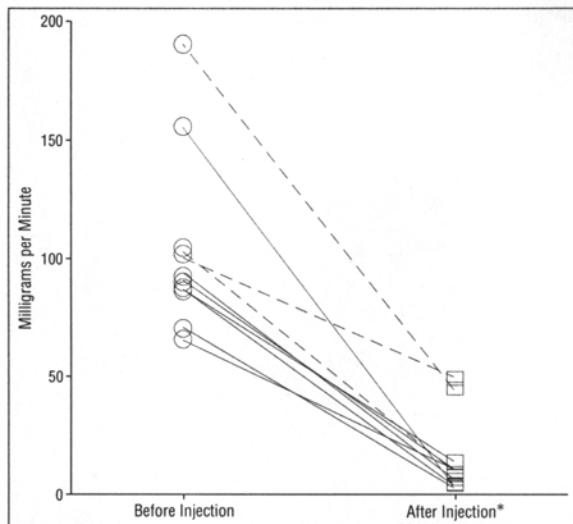


Figure 2. Spontaneous sweat secretion before and after botulinum toxin injection in 7 patients with axillary (solid lines) and 3 patients with palmar (dotted lines) sweating. The asterisk indicates $P < .001$.

was normal.¹⁴ However, the long-term effects of botulinum toxin on sweat glands remain to be established.

Interestingly, patients with axillary sweating did not notice a significant reduction of unpleasant odor after botulinum toxin injection, despite a marked decline of sweat production. This observation can be explained by the different transmitters involved in the innervation of eccrine and apocrine sweat glands.¹⁵ Sweat-producing eccrine sweat glands are innervated by cholinergic sympathetic nerve fibers, which are blocked by botulinum toxin. Apocrine sweat glands, however, are supplied by adrenergic sympathetic nerve fibers, which remain unaffected by botulinum toxin.

An optimal effect that lasts for at least 4 months without adverse effects holds promise that this novel therapy may become the treatment of choice for focal hyperhidrosis that is unresponsive to any other local or systemic drug therapy. The botulinum toxin (Botox) that we used in our study is currently being evaluated as an orphan drug in the United States. In particular, it has not been sufficiently tested in pregnancy. Therefore, at this stage, it must not be given to women of childbearing age

without contraception, to pregnant women, or to women during the lactation period.

In conclusion, intracutaneous administration of botulinum toxin is a novel, safe, and simple treatment for many patients with focal hyperhidrosis. It carries the potential to replace current invasive surgical procedures.

Accepted for publication September 8, 1997.

This study was supported in part by the Department of Neurology, University of Würzburg, and Allergan.

Reprints: Markus Naumann, MD, Department of Neurology, University of Würzburg, Josef-Schneider-Straße 11, 97080 Würzburg, Germany.

REFERENCES

- Gillespie JA. Extent and permanence of denervation produced by lumbar sympathectomy. *BMJ*. 1961;1:79-83.
- Shelley WB, Florence R. Compensatory hyperhidrosis after sympathectomy. *N Engl J Med*. 1960;263:1056-1058.
- Ambache N. A further survey of the action of *Clostridium botulinum* toxin upon different types of autonomic nerve fibers. *J Physiol*. 1951;113:1-17.
- Bushara KO, Park DM, Jones JC, Schutta HS. Botulinum toxin: a possible new treatment for axillary hyperhidrosis. *Clin Exp Dermatol*. 1996;21:276-278.
- Schneider P, Binder M, Berger T, Auff E. Botulinum A toxin injection in focal hyperhidrosis. *Br J Dermatol*. 1996;136:1160-1161.
- Naumann M, Flachenecker P, Bröcker EB, Toyka KV, Reiners K. Botulinum toxin for palmar hyperhidrosis. *Lancet*. 1997;349:252.
- Kennedy WR, Navarro X. Evaluation of sudomotor function by sweat imprint methods. In: Low PA, ed. *Clinical Autonomic Disorders*. Boston, Mass: Little Brown & Co Inc; 1993:253-261.
- Reinauer S, Neusser A, Schauf G, Hölzle E. Iontophoresis with alternating current and direct current offset (AC/DC iontophoresis): a new approach for the treatment of hyperhidrosis. *Br J Dermatol*. 1993;129:166-169.
- Jankovic J, Brin MF. Therapeutic uses of botulinum toxin. *N Engl J Med*. 1991;324:1186-1194.
- Drobik C, Laskawi R. Frey's syndrome: treatment with botulinum toxin. *Acta Otolaryngol*. 1995;115:459-461.
- Naumann M, Zellner M, Toyka KV, Reiners K. Botulinum toxin in the treatment of gustatory sweating. *Ann Neurol*. 1997;42:973-975.
- Blasi J, Chapman ER, Link E, et al. Botulinum toxin selectively cleaves the synaptic protein SNAP-25. *Nature*. 1993;365:160-163.
- Borodic GE, Ferrante RJ, Pearce LB, Alderson K. Pharmacology and histology of the therapeutic application of botulinum toxin. In: Jankovic J, Hallett M, eds. *Therapy With Botulinum Toxin*. New York, NY: Marcel Dekker Inc; 1994:119-157.
- Itoh Y, Yagishita S, Nakajima S, Nakano T. Congenital insensitivity to pain with anhidrosis: morphological and morphometrical studies on the skin and peripheral nerves. *Neuropediatrics*. 1986;17:103-110.
- Ogawa T, Low PA. Autonomic regulation of temperature and sweating. In: Low PA, ed. *Clinical Autonomic Disorders*. Boston, Mass: Little Brown & Co Inc; 1993:79-92.