

## Endoscopic Sympathectomy Treatment for Craniofacial Hyperhidrosis

Ming-Chien Kao, MD, DMSc; Yi-Long Chen, MD; Jue-Yi Lin, MD; Chung-Szu Hsieh, MD; Jui-Chang Tsai, MD, PhD

**Objective:** To present endoscopic T-2 sympathectomy as a minimally invasive therapy for craniofacial hyperhidrosis (CH).

**Design:** Follow-up study of 30 patients with CH treated by the new method in a 4-year period. The duration of follow-up was from 8 to 44 months (mean, 15 months).

**Setting:** University hospital.

**Patients:** Thirty consecutive patients with CH (18 men, 12 women) treated by the new method. All patients were essentially in good health except that they suffered from distressing CH to the extent that their daily activities were often disturbed. Their ages ranged from 7 to 63 years (mean age, 42.8 years).

**Intervention:** Endoscopic sympathectomy on both sides was carried out in a 1-stage operation for all patients.

**Main Outcome Measures:** The patients were interviewed 1 week and then 3 months after surgery and then followed up by telephone interview about the alleviation or recurrence of CH and complications.

**Results:** All of the treated patients obtained a satisfactory alleviation of CH. One case was complicated by a mild and transient ptosis of the left eye. No recurrence of CH was noticed during the follow-up period.

**Conclusions:** This therapeutic procedure is minimally invasive and effective. It causes minimal discomfort and was associated with no major complications in this series. The patients require only an overnight hospital stay and the operation scars are small. Endoscopic sympathectomy has proven to be an effective method in treating patients with distressing CH.

*Arch Surg.* 1996;131:1091-1094

SINCE THE introduction of the video endoscopic system in 1986, various endoscopic procedures have been developed. This system provides excellent illumination and good magnification of the operative field via a minimally invasive approach and allows surgical teamwork in performing a delicate operation. In 1990, we first developed the technique of video endoscopic sympathectomy to treat palmar hyperhidrosis (PH) and it was soon proven to be a simple and effective therapy for PH.<sup>1-4</sup> Clinically, we also encountered some patients who suffered from distressing hyperhidrosis in their heads and faces. Their faces often sweated excessively even under minor stress and hence their daily activities were seriously disturbed. The female patients were annoyed at not being able to apply cosmetics. They had tried various remedies but always remained frustrated. To our knowledge, no effective therapy for craniofacial hyperhidrosis (CH) has been

reported in the literature to date. The application of topical antiperspirant is not practical.<sup>5,6</sup> Systemic anticholinergic medication has only a temporary effect and has been disappointing because of its adverse effects.<sup>7</sup>

We noticed that most patients with PH treated by upper thoracic sympathectomy also experienced concomitant reduction in their facial sudomotor activity without the complication of ptosis.<sup>8-11</sup> Therefore, it seemed possible to alleviate excessive facial sweating without causing ptosis by endoscopic ablation of the T-2 sympathetic segment.

We first used this therapeutic technique in 1991 on a patient with distressing CH and obtained an encouraging result. We have previously reported the

See Patients and Methods on next page

From the Department of Surgery, Division of Endosurgery, National Taiwan University Hospital, Taipei.

## PATIENTS AND METHODS

Thirty patients with severe CH were treated during the past 4 years. Of the 30 patients, 8 also had PH. They were essentially in good health and without thyrotoxic features. Their faces sweated so much that their daily activities were frequently seriously disturbed. The female patients were annoyed at being unable to apply cosmetics. Of the 30 patients, 18 were male and 12 female. Their ages ranged from 7 to 63 years, with a mean of 42.8 years. Four female patients suffered from postmenopausal hot flushing. They continued to suffer from facial hyperhidrosis after relief of hot flushing with hormonal therapy.

Based on our abundant experience in the treatment of PH with endoscopic techniques,<sup>1-4</sup> we applied these same techniques to treat patients with CH. Under endotracheal general anesthesia, the patient was put in the supine position with both arms in abduction; blood oxygen saturation and palmar skin temperature were continuously monitored. After a few minutes of preoxygenation, the patient's endotracheal tube was temporarily disconnected from the ventilator. A conventional operating thoracoscope was then inserted into the upper thoracic cavity via the third or fourth intercostal space in the midaxillary line through a small incision. At this time, the lung would partially collapse spontaneously. The charge-coupled device camera and the video system were coupled to the thoracoscope. Subsequently, the upper thoracic cavity and the upper thoracic sympathetic trunk could be easily seen on the video system because of the temporary disconnecting of the endotracheal tube from the ventilator. The sympathetic trunk that overlaid the head of the second rib (T-2 segment) was identified and ablated by electrocoagulation (**Figure 1**).<sup>1,2</sup>

Throughout the procedure, blood oxygen-hemoglobin saturation was continuously monitored with a pulse oximeter. The ablation of the T-2 segment was mostly accomplished in a few minutes. During that short period of nonventilation, the blood oxygen saturation mostly remained in the safety range (above 95%). When the saturation occasionally decreased to 90%, we stopped the surgical procedure temporarily and applied the ventilator until the blood oxygenation level rose above 95% before we continued the ablation of the T-2 segment.

During cauterization of the T-2 segment, the ipsilateral palmar skin temperature rose gradually and continuously. When the palmar skin temperature showed a rise of approximately 3°C, it indicated an adequate facial denervation leading to an optimal therapeutic effect. At this point, the cauterization was considered sufficient and accomplished. The collapsed lung was gradually inflated to expel the residual air in the thorax via a small rubber drain, which was then removed when the lung was fully expanded. Therefore, a chest tube was not required postoperatively.

Sympathectomy on the other side was then carried out, and the procedures on both sides were accomplished within 30 minutes in 1 stage. A chest radiograph was taken a few hours after the operation to make sure that there were no intrathoracic complications. The patient was discharged from the hospital the next morning.

The patients were examined twice at the outpatient clinic, at 1 week and then 3 months after discharge, and then followed up by telephone interview to inquire about the results and complications of this treatment and the recurrence of CH.

preliminary results of 7 patients with CH who were successfully treated by this technique from 1991 to 1993.<sup>12</sup> In this communication, we will describe the surgical technique and present our experiences in treating a large series of patients with CH and the results of long-term follow-up. The rationale of the therapy will also be discussed.

## RESULTS

All 30 patients were successfully treated by endoscopic T-2 sympathectomy. None of these patients required a conversion to an open sympathectomy. Bilateral endoscopic sympathectomy was carried out in 1 stage and accomplished in 30 minutes.

Neither injury to the lung nor bleeding was encountered. All patients obtained satisfactory alleviation of CH. No ptosis or miosis occurred except in 1 patient who had left eye ptosis postoperatively. In this case, the T-2 segment was tightly covered by the adhering lung; therefore, the sympathetic trunk we cauterized might have been higher than the T-2 level. The ptosis, however, was mild and resolved 2 months later. The 8 patients who had PH in addition to CH also obtained complete relief of palmar sweating.

The duration of postoperative follow-up was from 8 to 44 months, with a mean of 15 months. All patients

were satisfied with the therapeutic results during the follow-up period. The female patients could apply cosmetics without the problem of smearing and dripping.

Most of the treated patients would complain of some degree of postsympathectomy compensatory hyperhidrosis, particularly when they worked in a warm and humid environment.<sup>3,4,8,10</sup> Fortunately, these compensatory hyperhidroses were mostly tolerable.<sup>4</sup> Neither gustatory sweating nor dryness of the hands was encountered in our series.

## COMMENT

Craniofacial hyperhidrosis is a pathological state of excessive local sweating in the head and face. The cause, like that of PH, remains unclear. Patients suffer greatly from distressing facial sweating to the point that their daily activities are often severely disturbed. So far, no effective therapy has been reported in the literature.

The sympathetic innervation to the eye is from the preganglionic fibers, mainly from the T-1 level of the spinal cord. The innervation to the head and neck is from T-1 to T-5, while that to the upper extremities is from T-2 to T-9. These preganglionic fibers ascend and synapse in the upper 3 thoracic sympathetic ganglia and cervical ganglia.<sup>13</sup> The T-2 segment sends most of its post-



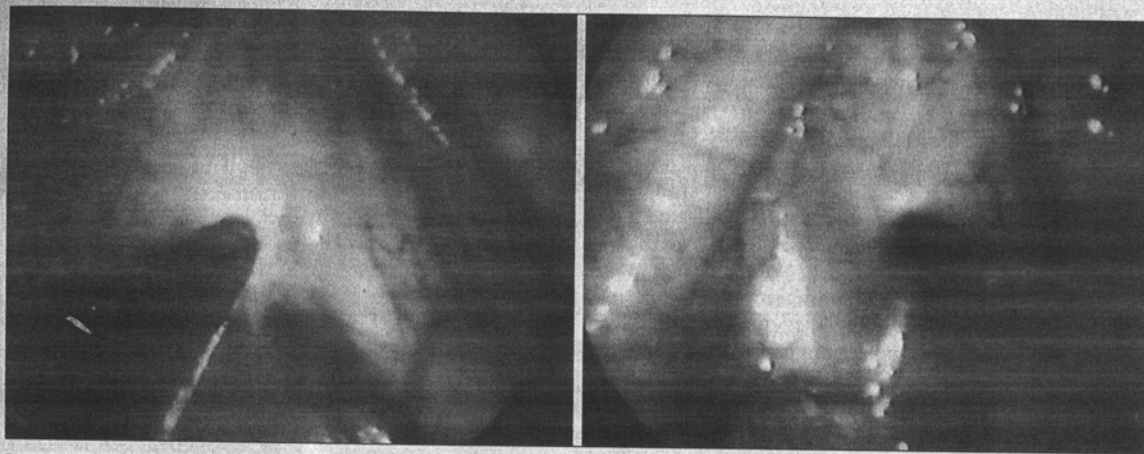


Figure 1. Endoscopic views of right upper thorax (left) and left upper thorax (right) showing the electrocoagulation on the T-2 sympathetic segment.

ganglionic fibers to the palm, some fibers to the face, but very few fibers to the eye (Figure 2). Consequently, endoscopic T-2 sympathectomy can successfully relieve PH and concomitantly result in a diminution of craniofacial sweating. The extent of sympathetic denervation to the eye after T-2 sympathectomy is not great enough to induce the complication of ptosis.<sup>3,4,8,10</sup> Therefore, elimination of craniofacial sweating without causing ocular complications can be achieved by T-2 sympathectomy.

As we have already mastered the technique of endoscopic sympathectomy for the treatment of PH,<sup>3,4</sup> we are confident in applying this technique to treat patients with CH. One of our patients had the postoperative complication of mild ptosis in the left eye because we had to coagulate his sympathetic trunk at a level higher than the T-2 segment owing to the fact that his T-2 segment and even the trunk above were covered by tight lung adhesion. The oculopupillary sympathetic fibers come from the stellate ganglion and a higher level of sympathetic chain that is usually located above the dome of the thorax or at its apex.<sup>3,4,11,12</sup> Therefore, to avoid ptosis, it is prudent to avoid cauterizing the sympathetic trunk high in the thoracic dome region.

In our service, we encountered about 1000 patients with PH and 25 patients with CH during the same period. The incidence of PH was much higher than that of CH, approximately 40 to 1. However, about one third of patients with CH also have a certain degree of PH. It was assumed that these patients might inherit a higher systemic sudomotor activity.

Most of the patients with CH are of middle age (mean age, 41.9 years), whereas patients with PH are younger.<sup>4</sup> Several female patients in our series had been misdiagnosed at first as having postmenopausal hot flushing, which is generally associated with a slight increase in facial sweating. However, unlike postmenopausal hot flushing, these patients had excessive craniofacial sweating, and their faces remained sweaty despite amelioration of hot flushing with hormonal therapy. It is obvious that the correct diagnosis of these patients originally should have been CH.

During electrocoagulation of the T-2 segment, we checked the patient's pupil size regularly. When the level

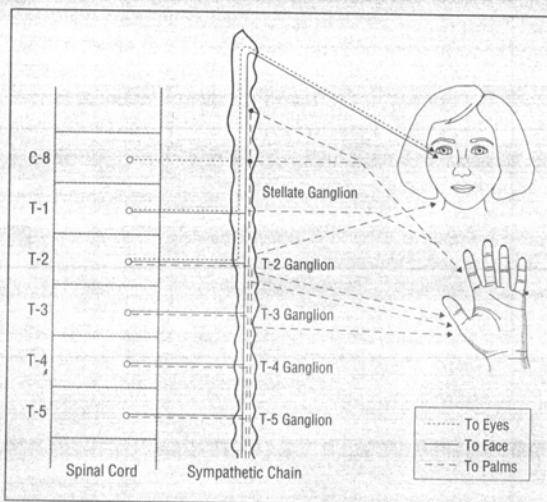


Figure 2. Schematic drawing of sympathetic innervation in the eye, face, and palm. It shows that the T-2 segment contributes the sympathetic supply of relatively differential domination to the eye, face, and palm.

of anesthesia was not very deep, the electrocoagulation applied to the T-2 segment would induce a slight dilatation of the ipsilateral pupil. This transient dilatation of the pupil was a result of the electrical stimulation of the T-2 segment, which contains a few sympathetic fibers ascending to the eye.<sup>13,14</sup> However, this phenomenon did not necessarily imply that ptosis would occur postoperatively because the destruction of the sympathetic supply to the eye by ablating the T-2 segment would not be great enough to induce ptosis.

Furthermore, the perfusion of patient's forehead skin had been studied with laser Doppler flowmeter during the procedure. No significant change of the perfusion was observed. The temperature of the patient's forehead skin was also monitored during the procedure and no obvious change could be found. It is believed that T-2 sympathectomy causes mild denervation of the craniofacial region<sup>12,14</sup> and would make only a trivial change in facial skin perfusion and temperature. The denervation effect was so trivial that it was easily disturbed by various

factors such as the temperature and ventilation of the operation room or the patient's condition. In contrast, T-2 sympathectomy, by destroying the segment that contains key ganglions to the hand, created a substantial sympathetic denervation of the palm that resulted in a significant elevation of palmar skin temperature. Based on our experience, as high as a 3°C rise in palmar skin temperature after T-2 sympathectomy properly indicated that an adequate reduction of facial sudomotor activity in patients with CH had been achieved.

It is clear that T-2 sympathectomy cannot completely denervate the craniofacial region, because the sympathetic supply to the area is not mainly from the T-2 level and because it is also possible that accessory or collateral sympathetic pathways beyond the T-2 segment exist.<sup>15,16</sup> Therefore, postoperative recurrence of CH might occur. However, based on our long-term observation of the patients with PH treated by T-2 sympathectomy, we believe that for CH T-2 sympathectomy may adequately alleviate facial sweating and enable the patient to be free of symptoms for a long time. In this study, more than one third of our patients had remained satisfied with the therapeutic results for longer than 1 year and we believe the results will be permanent. Based on the successful treatment of 30 patients with CH and satisfactory results without any major complications, we conclude that endoscopic T-2 sympathectomy is a simple, effective, and minimally invasive method for treating patients with distressing CH.

Corresponding author: Ming-Chien Kao, MD, Professor and Chief, Division of Neurosurgery, National Taiwan University Hospital, No. 7 Chung-Shan S Rd, Taipei, Taiwan.

## REFERENCES

1. Kao MC. Video endoscopic sympathectomy using a fiberoptic CO<sub>2</sub> laser to treat palmar hyperhidrosis. *Neurosurgery*. 1992;30:131-135.
2. Kao MC. Laser endoscopic sympathectomy for palmar hyperhidrosis. *Laser Surg Med*. 1992;12:308-312.
3. Kao MC, Tsai JC, Lai DM, Hsiao YY, Chiu MJ. Autonomic activities in hyperhidrosis patients before, during, and after endoscopic laser sympathectomy. *Neurosurgery*. 1994;34:262-268.
4. Kao MC, Lee WY, Yip KM, Hsiao YY, Lee YS, Tsai JC. Palmar hyperhidrosis in children: treatment with video endoscopic laser sympathectomy. *J Pediatr Surg*. 1994;29:387-391.
5. Cullen SI. Topical methenamine therapy for hyperhidrosis. *Arch Dermatol*. 1975; 111:1158-1160.
6. Shelly WB, Hurley HJ. Studies on topical antiperspirant control of axillary hyperhidrosis. *Acta Derm Venereol*. 1975;55:241-260.
7. Shelly WB, Horvath PN. Comparative study on the effect of anticholinergic compounds on sweating. *J Invest Dermatol*. 1951;13:267-274.
8. Adar R, Kurchin A, Mozes M. Palmar hyperhidrosis and its surgical treatment. *Ann Surg*. 1977;186:34-41.
9. Cloward RB. Hyperhidrosis. *J Neurosurg*. 1969;30:545-551.
10. Shih CJ, Wang YC. Thoracic sympathectomy for palmar hyperhidrosis: report of 457 cases. *Surg Neurol*. 1978;10:291-296.
11. Kux M. Thoracic endoscopic sympathectomy in palmar and axillary hyperhidrosis. *Arch Surg*. 1978;113:264-266.
12. Kao MC, Chen YL, Lee YS, Hung CC, Huang SJ. Craniofacial hyperhidrosis treated with video endoscopic sympathectomy. *J Clin Laser Med Surg*. 1994; 12:93-95.
13. Ray BS, Hinsey JC, Geohegan WA. Observations on the distribution of the sympathetic nerves to the pupil and upper extremity as determined by stimulation of the anterior roots in man. *Ann Surg*. 1943;118:647-655.
14. Hardy RW Jr, Bay JW. Surgery of the sympathetic nervous system. In: Schmidek HH, Sweat WH, eds. *Operative Neurosurgical Techniques*. 2nd ed. Orlando, Fla: Grune & Stratton; 1988:1271-1280.
15. Alexander WF, Kuntz A, Henderson WP, Ehrlich E. Sympathetic ganglion cells in ventral nerve roots: their relation to sympathectomy. *Science*. 1949; 109:484.
16. Skoog T. Ganglia in communicating rami of the cervical sympathetic trunk. *Lancet*. 1947;2:457-460.

## IN OTHER AMA JOURNALS

### ARCHIVES OF INTERNAL MEDICINE

**Therapeutic Approaches in Patients With Candidemia: Evaluation in a Multicenter, Prospective, Observational Study**  
M. Hong Nguyen, MD; James E. Peacock, Jr, MD; David C. Tanner, MD; Arthur J. Morris, MD; Minh Ly Nguyen, MD; David R. Snyderman, MD; Marilyn M. Wagener, MS; Victor L. Yu, MD

**Objectives:** To evaluate the morbidity and mortality of *Candida* fungemia and to assess the efficacy of low- vs high-dose amphotericin B and fluconazole vs amphotericin B in patients with candidemia.

**Methods:** Multicenter, prospective, observational study of 427 consecutive patients with candidemia.

**Results:** The mortality rate for patients with candidemia was 34%. The mortality rate for patients with catheter-related candidemia in whom the catheters were retained was significantly higher than that of patients in whom the catheters were removed (41% vs 21%,  $P < .001$ ). We found no overall difference in mortality in patients treated with low-dose (total amphotericin B dose of  $\leq 500$  mg) (13%) vs high-dose amphotericin B (total amphotericin B dose of  $> 500$  mg) (15%), but the group treated with a low dose had fewer side effects (40%) than those treated with a high dose (55%) ( $P = .03$ ). Fluconazole was as efficacious as amphotericin B in the therapy of candidemia, even when stratified by risk factors for mortality. Fewer side effects were seen with fluconazole (12%) compared with amphotericin B (44%) ( $P < .001$ ).

**Conclusions:** In selected patients with candidemia, low-dose amphotericin B was as efficacious as high-dose amphotericin B. Based on other studies and ours, fluconazole seems to be an alternative therapeutic option to amphotericin B in selected patients. (*Arch Intern Med*. 1995;155:2429-2435)

Reprint requests to University of Pittsburgh, Division of Infectious Diseases, W931 Montefiore, Pittsburgh, PA 15213 (Dr Yu).