

# Local Procedural Approaches for Axillary Hyperhidrosis



Dee Anna Glaser, MD\*, Timur A. Galperin, DO

## KEYWORDS

• Hyperhidrosis • Liposuction-curettage • Microwave thermolysis • Minimally invasive • Surgery

## KEY POINTS

- Surgical procedures can provide long-lasting relief from axillary hyperhidrosis.
- Local or tumescent anesthesia is most commonly used for local procedures of the axilla.
- Most of these procedures are limited to treating the axillary region of the body.
- Starch-iodine testing is valuable to identify the area of treatment, but the hair-bearing skin can be used as a landmark for treatment as well.
- Downtime is minimal, typically 2 to 6 days, depending on the procedure.

## INTRODUCTION

When topical options for axillary hyperhidrosis (HH) have failed, botulinum toxin is an effective, safe, and well-tolerated, although temporary, treatment option. For long-lasting or permanent efficacy, some patients turn to local procedures, such as superficial liposuction or manual curettage, or more invasive local surgery. Local surgical treatment is divided into 3 categories: (1) excision of skin and glandular tissue, (2) curettage or liposuction procedures to remove the subcutaneous sweat glands, or (3) a combination of limited skin excision with glandular tissue removal.<sup>1</sup> Complete skin excision is performed infrequently, because improved minimally invasive surgical techniques have become effective with fewer long-term complications.<sup>2</sup> The nonresponder rate varies from 2% to 20% with minimally invasive surgery

and is likely the result of inadequate mapping of the hyperhidrotic area or inadequate surgical technique.<sup>2</sup> Newer, minimally invasive treatments have become available, such as microwave energy thermolysis.

## PATIENT EVALUATION OVERVIEW

A thorough HH history should be obtained from the patient, including age of onset of HH, location and symmetry of sweating, aggravating/alleviating factors, previous treatments for HH, family history of HH, and current medications that may exacerbate the condition. A physical examination should be performed to rule out a possible secondary cause of HH that needs to be treated. A starch-iodine test is then performed to identify the dimensions of the involved area for treatment. The Minor starch-iodine test is a cheap and

Disclosure: D.A. Glaser has served as advisor for Allergan, Galderma, Miramar Labs, and Unilever. She has been an investigator and received research grants from Allergan, Miramar Labs, and Ulthera. T.A. Galperin has nothing to disclose.

Department of Dermatology, Saint Louis University School of Medicine, 1402 South Grand Boulevard-ABI, St Louis, MO 63104, USA

\* Corresponding author.

E-mail address: glasermd@slu.edu

Dermatol Clin 32 (2014) 533–540

<http://dx.doi.org/10.1016/j.det.2014.06.014>

0733-8635/14/\$ – see front matter © 2014 Elsevier Inc. All rights reserved.

simple procedure commonly used to detect focal areas of sweating. The affected area is first dried, then an iodine solution is brushed onto the skin and allowed to dry. A starch powder, such as corn starch, is peppered on top, and the area is observed for a few minutes. Purple-black dots develop when sweat interacts with the starch and iodine. If a positive starch-iodine test cannot be obtained, the hair-bearing portion of the axilla should be treated.

The amount of axillary sweating can be assessed using the patient-reported Hyperhidrosis Disease Severity Scale (HDSS) (Table 1). The HDSS can also be obtained during the postoperative period to assess treatment success. Gravitric (weight-based) assessment is an objective measurement typically performed in research studies but is not practical for routine clinical use.

In addition, surgical risks need to be ascertained before considering which procedure may be best suited for the patient. Antiplatelet therapies and bleeding diathesis are relative contraindications. Patients with significant arthritis or previous injury to the shoulder area may limit access to the axillary vault for certain procedures, and pain in the area may limit the patient's ability to maintain proper arm position during surgery, even if good range of motion is present.

## MANAGEMENT GOALS

The goals of therapy are to provide a permanent or long-lasting solution for axillary HH, with a minimally invasive procedure that is cost-effective, easily accessible, and has minimal side effects and downtime.

## SURGICAL TREATMENT OPTIONS AND PROCEDURE

### Excision

Surgical excision can either be a radical excision of the skin and glandular tissue (RSE) (ie, en bloc

resection), or a limited skin excision with glandular tissue removal (LSE), such as the modified Shelley procedure. Surgical complication rates from RSE are high, and the procedure is rarely performed.<sup>1</sup> The relapse rate can vary. A study of 125 patients<sup>3</sup> undergoing LSE found a 12.8% relapse rate.

RSE can be performed via several different surgical techniques, each differing in the method of axillary skin removal and type of wound closure.<sup>4</sup> RSE can be performed under tumescent anesthesia, and the wounds sutured, generally requiring a subcutaneous drain for 1 to 2 days after treatment.<sup>4</sup>

Excessive sweating, as measured by gravimetric assessment, at 12 months after treatment is reduced by about 65%.<sup>4</sup> In studies, the average aesthetic outcome reported by patients was graded as moderate. Side effects of treatment include hematoma formation (20%), paresthesia (33.3%), focal alopecia (100%), and skin infection (13%).<sup>4</sup> Poor aesthetic outcomes, with scarring and skin retraction, which can lead to a decreased range of motion of the shoulder,<sup>5</sup> and long recovery times are 2 reasons that en bloc resections are rarely, if ever, performed.

With the skin-sparing technique (LSE), surgeons can perform the procedure on 1 axilla at a treatment session,<sup>1,3</sup> or both axillae can be treated simultaneously.<sup>4</sup> Antibiotic prophylaxis can be given an hour before the procedure, if deemed necessary. The area of maximal sweating is identified via the Minor starch-iodine test, and then, the axilla is anesthetized with lidocaine 1% and epinephrine 1:100,000<sup>1</sup> or tumescent anesthesia.<sup>4</sup> The elliptical area of maximal sweating, approximately 4 cm × 1 cm in diameter (horizontally), is excised down to the subcutaneous fat. The adjacent hair-bearing area of excessive sweating is undermined with Metzenbaum scissors to the affected edges, and the wound edges are everted to expose the 1-mm to 2-mm pink, papular sweat glands adhering to the dermis.<sup>1</sup> Sweat glands are cut out with curved scissors to defat the dermis, and the wound is closed with sutures. A subcutaneous drain is required for 1 to 2 days after treatment. A figure-of-eight dressing is applied for 10 days,<sup>4</sup> or a compression dressing for 24 hours.<sup>3</sup>

Excessive sweating, as measured by gravimetric assessment, at 12 months after treatment was reduced by a mean of 63% in 1 case series.<sup>4</sup> An early case series,<sup>1</sup> using a subjective, patient-assessed measure of sweat reduction after treatment, found a mean sweat reduction of 65%. The average aesthetic outcome reported by patients was graded as good,<sup>4</sup> 58.4% of patients

**Table 1**  
HDSS

### How Would You Rate the Severity of Your Hyperhidrosis?

HDSS Score	Definition
1	Never noticeable, never interferes
2	Tolerable, sometimes interferes
3	Barely tolerable, frequently interferes
4	Intolerable and always interferes

were satisfied with treatment, and 82.4% would choose the same procedure again.<sup>3</sup> The mean amount of time to return to work is reported to vary from 4 to 8.8 days.<sup>1,3</sup>

Side effects and scarring are less prevalent than with en bloc excision. The mean scar length is 5 cm, and scar formation does not lead to functional impairment, compared with a scar length of 9.3 cm, and a relatively high prevalence of functional impairment in the RSE group.<sup>3,4</sup> Side effects include hematoma formation (18.2%), paresthesia (27.3%), focal alopecia (100%), seroma formation (27.3%), fibrotic bridles (27.3%), skin erosion (36.4%), skin infection (5.6%), hypertrophic scarring (13/99), and flap necrosis (18.2%).<sup>3,4</sup>

### Liposuction

Because the eccrine glands are located at the superficial subcutaneous plane, liposuction procedures have been used to remove the sweat glands without having to excise tissue. Liposuction has been used safely, and with moderate long-term efficacy in axillary HH. Patients can receive antibiotic prophylaxis with ciprofloxacin 500 mg orally  $\times$  1 dose an hour before the procedure,<sup>6</sup> although most physicians do not pretreat with antibiotics. Like other procedures, a starch-iodine test is helpful to identify the area of HH. Two small incisions are made in the superior and inferior borders of the axilla to deliver tumescent anesthesia. Once the skin is visibly blanched, the suction cannula is used to superficially remove the subcutaneous fat. Physicians have a variety of cannulas to choose from (Fig. 1), but in general, the more aggressive cannulas provide greater reduction of sweat, although they may be associated with



**Fig. 1.** Liposuction cannulas showing different configurations.

higher risks of adverse events.<sup>6</sup> The hole of the cannula is oriented toward the skin surface, and the sweat glands are scraped away from the underside of the dermis using a back-and-forth motion in a crisscross pattern.<sup>7,8</sup> Incisions are generally not closed, but are left open for drainage. A compression bandage can be applied for 24 hours.<sup>6,7</sup>

In 1 study comparing 3 different cannulas,<sup>6</sup> the investigators found a 44% and 49% reduction in sweating, obtained by gravimetric measurements, with a 1-hole and 3-hole cannula, respectively. The relapse rate with liposuction can be as high as 40% several months after treatment.<sup>7</sup> Side effects are minor and temporary. They include bruising, hematoma formation (43%), skin erosion (7%–14%), bridle formation (21%), paresthesia (43%–50%), and partial alopecia (14%).<sup>6,8</sup>

### Liposuction-Curettage

Liposuction-curettage (LC) has been safely and effectively performed for many years. There are several different treatment techniques, which differ in their type and size of incisions, type of cannula and curette used, and the aggressiveness of the procedure. The experience of the surgeon is also an important factor. Tumescent anesthesia is administered, and small incisions are made into the central and upper inner axilla.<sup>3,4,9</sup> Alternatively, a modified technique can be used, in which 4 or 5 2-mm, evenly spaced, vertically oriented incisions are made using a punch biopsy instrument 1 cm beyond the lateral margin of the axilla, and 4 or 5 similarly sized and spaced incisions are made horizontally 1 cm beyond the inferior margin.<sup>10</sup> LC is performed using a liposuction device and a sharp, rasping-type cannula applied to the dermal-subcutaneous interface. Blunt cannulas may not remove sweat glands as proficiently as cannulas with curettage.<sup>3,4,9</sup> Back-and-forth strokes are performed with an upward tension, and the surgeon's thumb and forefinger provide pressure on the skin at either end of the cannula.<sup>4,10</sup>

Intraoperative indicators of sufficient LC include a complete elevation of the skin from subcutaneous fat, lividity of the skin, and no fat adhering to the dermis.<sup>9,10</sup> Incisions are closed with either Steri-Strips™ (3M, St. Paul, MN) or sutures but can be left open for better drainage. A compression bandage for 24 hours or a figure-of-eight dressing for 10 days is applied.<sup>3,4</sup>

Excessive sweating, as measured by gravimetric assessment, at 6 to 12 months after treatment, can be reduced by 60.4% to 69% in 89% to 93% of patients.<sup>4,6,10</sup> The mean HDSS score

of 3.05 decreased to 2.75 6 months after treatment, which was statistically significant.<sup>10</sup> The aesthetic outcome reported by patients was graded as either very good or good,<sup>4</sup> and 78.4% to 84% of patients were completely satisfied or satisfied with the procedure<sup>3,4,9</sup>; 94.6% of patients would choose the same procedure again.<sup>3</sup> The relapse rate is approximately 14.5%, and the mean amount of time to return to work was only 1.3 days.<sup>3</sup>

Side effects of treatment are mild and temporary, and include hematoma formation (20%–78.4%), paresthesia (11.8%–26.7%), focal alopecia (7.8%–60%), seroma formation (6.7%–13.7%), skin erosion (20%–32%), bridle formation (10.8%–53.3%), and flap necrosis (6.7%).<sup>3,4,9</sup> There is only a small risk of skin infection. Skin ulceration and full-thickness skin necrosis can occur with aggressive LC, without any added efficacy.<sup>11</sup> Scarring is minimal, with the average scar length of 1 cm, and without hypertrophy or functional impairment.<sup>3,4</sup>

The exact duration of efficacy of LC is difficult to ascertain, because past studies had many variations in surgical expertise, surgical techniques, methods of measuring efficacy, and no consistent follow-up of patients past 1 year.

### Curettage

There are several different treatment techniques, which differ in their type and size of incisions, type of cannula and curette used, and the aggressiveness of the procedure. Tumescence anesthesia is used, followed by a 2-cm to 3-cm incision made caudally from the marked zone,<sup>12</sup> or 2 or 3 5-mm incisions can be made at the margins of the axillae.<sup>13</sup> The marked area is undermined using Metzenbaum scissors, and a sharp, gynecologic<sup>12</sup> or number 2 curette<sup>13</sup> is used within the dermis. After curettage, the wound is closed with subcutaneous and superficial sutures, and a suction drained is placed within the axilla until secretions are lower than 10 mL/d.<sup>12</sup> Conversely, with 2 or 3 small incisions, wounds can be closed with adhesive strips, and a compression bandage applied for 24 hours.<sup>13</sup>

At 6 months after treatment, 36.4% of patients had a very good outcome, and 29.9% of patients had a good outcome, based on subjective assessment.<sup>12</sup> Excessive sweating, as measured by gravimetric assessment, at a median 11 months after treatment can be reduced by more than 50% in 93% of patients<sup>13</sup>; 90.9% of patients would recommend the procedure to others.<sup>12</sup> The relapse rate with this procedure is approximately 29%.<sup>13</sup>

Side effects include infection (2.2%), epidermal necrosis (2.2%), hematoma formation (13.3%), a markedly visible scar (27%), paresthesia (33%), partial alopecia (44%), hyperpigmentation (33%), and skin ulceration (12%).<sup>12,13</sup>

### MiraDry

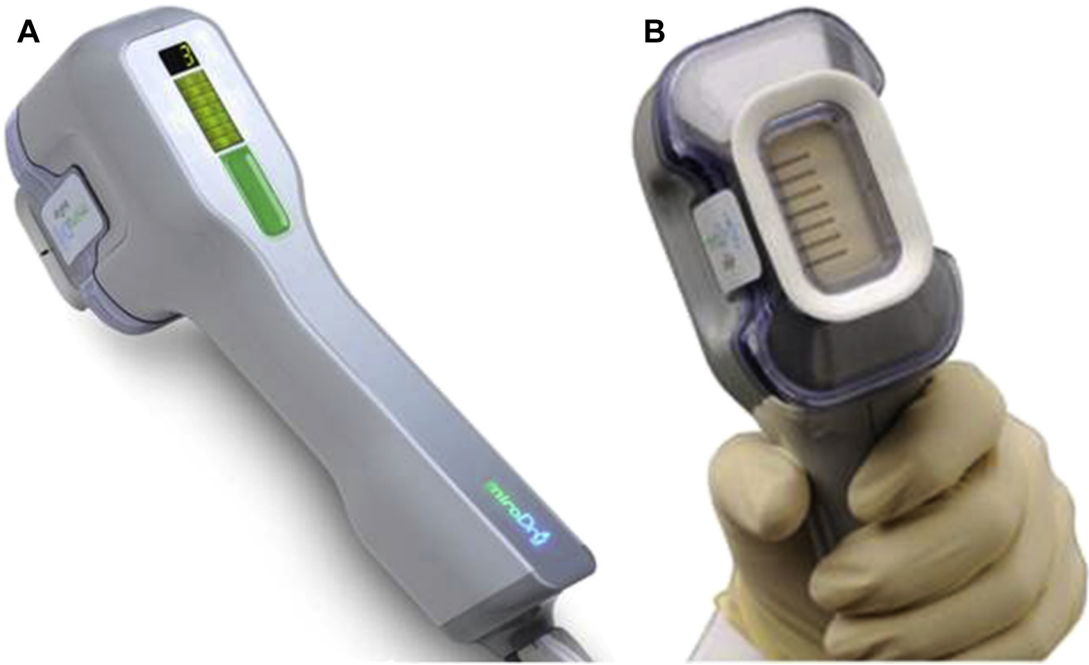
The MiraDry device is a new, nonsurgical treatment that is cleared by the US Food and Drug Administration (FDA) for axillary HH. It uses microwave energy to destroy eccrine sweat glands. Microwave energy is preferentially absorbed by tissue with a high water content, such as the sweat glands. The microwave energy leads to rapid molecular rotation, which generates frictional heat and cellular thermolysis.<sup>14,15</sup>

The device consists of a console, a handpiece, and a single-use biotip (**Fig. 2**). The antennae, within the handpiece, focus microwave energy on to the dermal-adipose interface, regardless of skin thickness.<sup>14,15</sup> There is simultaneous cooling and monitoring of the skin temperature, during the energy cycle, to avert thermal transfer of heat into the epidermis. There are 5 energy settings, which regulate the duration and depth of heat to be delivered, and the vacuum system within the biotip helps to stabilize the skin during the treatment.<sup>14</sup>

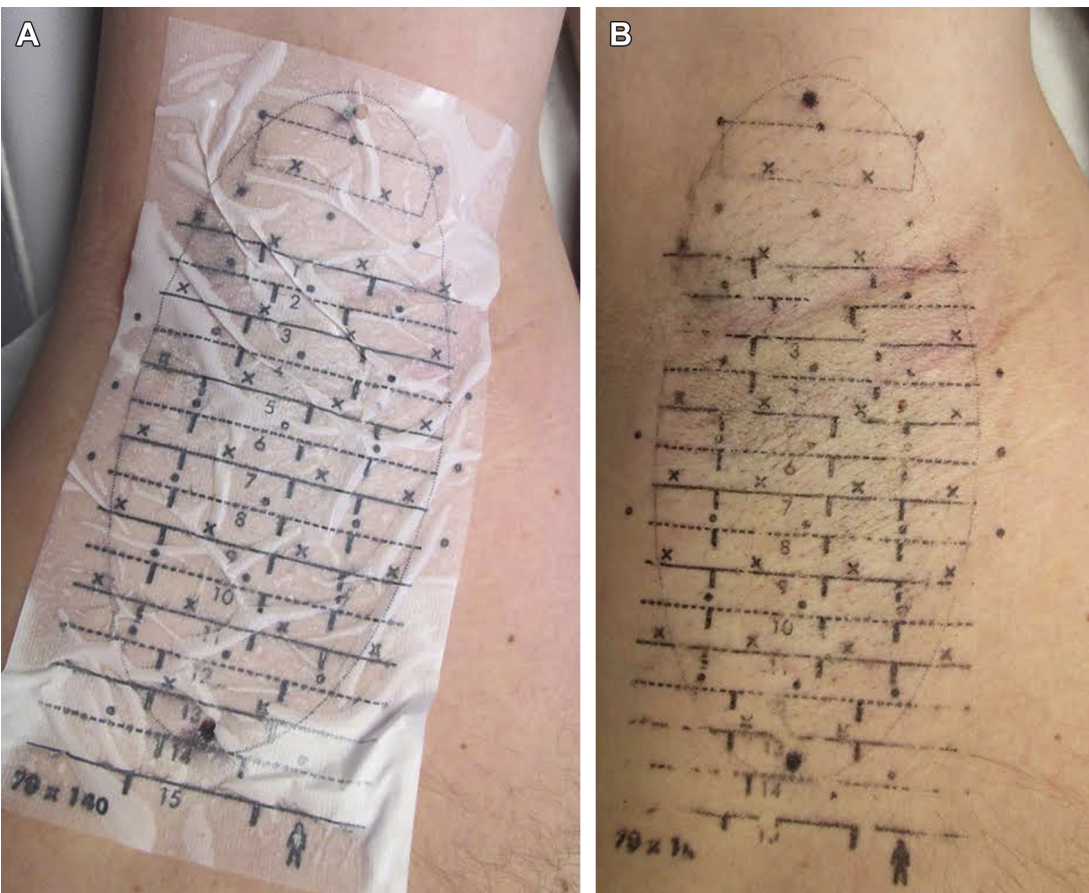
A few days before the procedure, patients should shave their axillae, and 1 to 2 hours before the procedure, patients should take ibuprofen 800 mg to minimize posttreatment tenderness and edema. A starch-iodine test is performed to identify the area of prominent sweating, after this, the axillary vault is measured with a supplied grid. Alternatively, the hair-bearing skin can be treated. The grid measures the length and width of the vault in millimeters. A temporary template, fitting the specified measurements, is applied to the vault to identify the treatment zones and injection sites for anesthesia (**Fig. 3**).<sup>14</sup> The axillae are injected with lidocaine 1% and epinephrine 1:100,000, up to the maximum level of 7 mg/kg. The discomfort associated with lidocaine injection can be lessened by buffering the lidocaine with sodium bicarbonate.

The initial energy setting can be set to 1 (lowest), 2, or 3. We prefer to perform the initial treatment at level 3. The biotip automatically starts at the lowest energy setting in the upper inner axilla, where the skin is thinnest and the overlying nerves are closer to the skin surface. After the upper zones are treated, the energy level is automatically adjusted to the specified level for the remainder of treatment. Each zone takes approximately 45 seconds to treat (**Fig. 4**), and

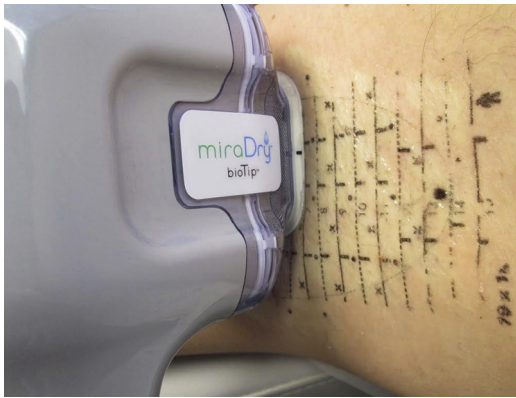




**Fig. 2.** (A, B) Handpiece and single-use biotip used for microwave thermolysis. (Courtesy of Miramar Labs, Santa Clara, CA; with permission.)



**Fig. 3.** (A, B) The appropriately sized template is placed onto the axillary vault. Alcohol is dabbed on to the tissue to transfer the template pattern to the axilla.



**Fig. 4.** As each zone is treated, cooling plates in the biotip cool the epidermis. (Courtesy of Miramar Labs, Santa Clara, CA; with permission.)

it takes 20 to 30 minutes per axilla, depending on the axilla size and energy level. After the treatment, patients are given an ice pack wrapped in gauze or a paper towel and instructed to keep it in place for 15 to 20 minutes at a time every 1 to 2 hours, for the first 48 hours after treatment. Patients are also instructed to continue nonsteroidal antiinflammatory agents such as ibuprofen 400 mg every 4 to 6 hours for the first 48 hours. Patients require 2 treatment sessions, with a second treatment performed 3 months after the initial one.<sup>16</sup> The treatment delay allows time for healing and fibrosis, which further reduces the number of eccrine and apocrine glands.<sup>16,17</sup> Rarely, a third treatment is performed to achieve the desired outcome.

MiraDry is effective in reducing excess sweating. From the baseline HDSS assessment, 94% of patients experienced a 1-point decrease in their HDSS score,<sup>16</sup> and 55% to 83.3% experienced a 2-point or greater decrease in their HDSS score at 12 months after treatment.<sup>16,18</sup> Based on gravimetric assessments, 90% of patients experienced a 50% or greater reduction in axillary sweating, with an average reduction of 81.7%.<sup>16</sup> At 12 months after treatment, 85.5% of patients were satisfied with their treatment outcome.<sup>16</sup>

Improvement of axillary odor has been noted by patients.<sup>18</sup> Lee and colleagues reported using the microwave device on 11 Asian patients: 3 with HH only, 3 with HH and osmidrosis, and 5 with osmidrosis alone. The HDSS scores improved in all patients with HH (1-point to 3-point decrease in the HDSS) and axillary odor improved in all patient with osmidrosis. The improvement in odor was subjective and rated on a 4-point scale, with a

1-point to 3-point decrease reported by the patients. The investigators have treated a limited number of patients whose main complaint is axillary body odor with the device, and patients have described improvement, but clearly more studies are needed.

Common and minor side effects include edema, redness from vacuum suction, and axillary tenderness/pain for several days' duration.<sup>16</sup> Altered sensation (numbness, tingling) in the upper arm or axilla can occur and lasts for approximately 5 weeks.<sup>16,17</sup> Less common side effects reported include blisters or burns at the treatment site, skin irritation/rash, axillary bumps, patchy alopecia, and mild compensatory sweating.<sup>16,17</sup> Patients can occasionally have edema outside the treatment area, and rarely, they can have temporary nerve injury.

### EVALUATION OF OUTCOME, ADJUSTMENT OF TREATMENT, AND LONG-TERM RECOMMENDATIONS

To our knowledge, there are only a few randomized controlled trials comparing the efficacy of 2 procedures concurrently, which makes it difficult to assess the relative benefit of 1 procedure over another. A single randomized trial<sup>4</sup> compared the effectiveness, both histologically and gravimetrically, of RSE, LSE, and LC. The results showed that all 3 treatments had similar efficacy (minor differences were not statistically significant), but LC had the least amount of side effects, minimal scarring, and the least amount of down time. A randomized trial comparing LC versus curettage alone<sup>19</sup> found LC to be more effective, and with a similar side effect profile. Based on the available patient outcomes data, LC is the single best minimally invasive surgical treatment of axillary HH, in terms of efficacy, aesthetic outcome, and side effect profile.

The risk profile for RSE procedures does not justify their use, and procedures such as LC should be performed only by experienced surgeons, because the efficacy and safety of such procedures are operator dependent.

Since the initial advent of the invasive and minimally invasive surgical procedures for axillary HH, safer alternative treatments have become available, such as microwave thermolysis. When comparing the effectiveness, side effects, and patient satisfaction of the current procedural treatments for axillary HH (**Table 2**), microwave thermolysis may be the best available procedural treatment option, if the patient prefers a long-term solution.

**Table 2**  
**A comparison of the invasive and minimally invasive procedures for axillary HH**

Procedure	Mean Reduction in HDSS	Mean Reduction with Gravimetric Measurements (%)	Mean Patient-Rated Satisfaction (%)	Mean Relapse Rate (%)	Common Side Effects (Mean %)	Less Common Side Effects (Mean %)
Liposuction	—	46.5	—	40	Bruising, hematoma formation (43), bridle formation (21), paresthesia (46.5)	Skin erosion (10.5), partial alopecia (14)
LC	0.30-point reduction	66	82.1 completely satisfied or satisfied	14.5	Paresthesia (19.8), hematoma (49.2), skin erosion (26.5), alopecia (33.9), bridle formation (29.3)	Flap necrosis (6.7), seroma formation (12.5), wound infection
Curettage	—	50	—	29	Hematoma (13.3), markedly visible scar (27), paresthesia (33), partial alopecia (44), hyperpigmentation (33)	Wound infection (2.2), epidermal necrosis (2.2), skin ulceration (12)
RSE	—	65.3	—	—	Hematoma (20), paresthesia (33.3), alopecia (100), large scar (100)	Wound infection (13)
LSE	—	62.9	58.4 satisfied	12.8	Hematoma (18.2), paresthesia (27.3), alopecia (100), seroma formation (27.3), bridle formation (27.3), skin erosion (36.4), flap necrosis (18.2)	Wound infection (5.6)
MiraDry	94 had a 1-point reduction	81.7	85.5 satisfied	—	Edema/erythema (90), paresthesia (65), patchy alopecia (26)	Blister formation (4.9), skin irritation (4.9), axillary bumps (2.5), mild compensatory sweating (2.5)

## SUMMARY

Patients prefer treatments that are least invasive, require minimal downtime, and have good cosmetic results. Surgical treatments are effective at reducing excessive sweating, but require time for recovery after procedure, are operator dependent, and can have poor cosmetic outcomes. Treatment with microwave thermolysis is effective, minimally invasive, requires limited downtime, and has good cosmetic outcomes. Microwave thermolysis is the best minimally invasive procedural treatment of axillary HH and is FDA-cleared for such treatment. Other newer minimally invasive technologies are forthcoming, such as focused ultrasonography and fractional microneedle radio-frequency, which could prove to be efficacious as well.

## REFERENCES

1. Lawrence CM, Lonsdale Eccles AA. Selective sweat gland removal with minimal skin excision in the treatment of axillary hyperhidrosis: a retrospective clinical and histological review of 15 patients. *Br J Dermatol* 2006;155(1):115–8. <http://dx.doi.org/10.1111/j.1365-2133.2006.07320.x>.
2. Bechara FG, Sand M, Altmeyer P. Characteristics of refractory sweating areas following minimally invasive surgery for axillary hyperhidrosis. *Aesthetic Plast Surg* 2008;33(3):308–11. <http://dx.doi.org/10.1007/s00266-008-9261-4>.
3. Wollina U, Köstler E, Schönlebe J, et al. Tumescence suction curettage versus minimal skin resection with subcutaneous curettage of sweat glands in axillary hyperhidrosis. *Dermatol Surg* 2008;34(5):709–16. <http://dx.doi.org/10.1111/j.1524-4725.2008.34132.x>.
4. Bechara FG, Sand M, Hoffmann K, et al. Histological and clinical findings in different surgical strategies for focal axillary hyperhidrosis: histologic and clinical findings. *Dermatol Surg* 2008;34(8):1001–9. <http://dx.doi.org/10.1111/j.1524-4725.2008.34198.x>.
5. Connolly M, de Berker D. Management of primary hyperhidrosis: a summary of the different treatment modalities. *Am J Clin Dermatol* 2003;4(10):681–97.
6. Bechara FG, Sand M, Sand D, et al. Surgical treatment of axillary hyperhidrosis: a study comparing liposuction cannulas with a suction-curettage cannula. *Ann Plast Surg* 2006;56(6):654–7. <http://dx.doi.org/10.1097/01.sap.0000205771.40918.b3>.
7. Lee MR, Ryman WJ. Liposuction for axillary hyperhidrosis. *Australas J Dermatol* 2005;46(2):76–9.
8. Swinehart JM. Treatment of axillary hyperhidrosis: combination of the starch-iodine test with the tumescent liposuction technique. *Dermatol Surg* 2000;26(4):392–6.
9. Bechara FG, Sand M, Tomi NS, et al. Repeat liposuction-curettage treatment of axillary hyperhidrosis is safe and effective. *Br J Dermatol* 2007;157(4):739–43. <http://dx.doi.org/10.1111/j.1365-2133.2007.08092.x>.
10. Ibrahim O, Kakar R, Bolotin D, et al. The comparative effectiveness of suction-curettage and onabotulinumtoxin-A injections for the treatment of primary focal axillary hyperhidrosis: a randomized control trial. *J Am Acad Dermatol* 2013;69(1):88–95. <http://dx.doi.org/10.1016/j.jaad.2013.02.013>.
11. Bechara FG, Sand M, Hoffmann K, et al. Aggressive shaving after combined liposuction and curettage for axillary hyperhidrosis leads to more complications without further benefit. *Dermatol Surg* 2008;34(7):952–3. <http://dx.doi.org/10.1111/j.1524-4725.2008.34185.x>.
12. Rompel R, Scholz S. Subcutaneous curettage vs. injection of botulinum toxin A for treatment of axillary hyperhidrosis. *J Eur Acad Dermatol Venereol* 2001;15(3):207–11.
13. Proebstle TM, Schneiders V, Knop J. Gravimetrically controlled efficacy of subcorial curettage: a prospective study for treatment of axillary hyperhidrosis. *Dermatol Surg* 2002;28(11):1022–6.
14. Jacob C. Treatment of hyperhidrosis with microwave technology. *Semin Cutan Med Surg* 2013;32(1):2–8.
15. Johnson JE, O'Shaughnessy KF, Kim S. Microwave thermolysis of sweat glands. *Lasers Surg Med* 2012;44(1):20–5. <http://dx.doi.org/10.1002/lsm.21142>.
16. Chih-Ho Hong H, Lupin M, O'Shaughnessy KF. Clinical evaluation of a microwave device for treating axillary hyperhidrosis. *Dermatol Surg* 2012;38(5):728–35. <http://dx.doi.org/10.1111/j.1524-4725.2012.02375.x>.
17. Glaser DA, Coleman WP, Fan LK, et al. A randomized, blinded clinical evaluation of a novel microwave device for treating axillary hyperhidrosis: the dermatologic reduction in underarm perspiration study. *Dermatol Surg* 2012;38(2):185–91. <http://dx.doi.org/10.1111/j.1524-4725.2011.02250.x>.
18. Lee SJ, Chang KY, Suh DH, et al. The efficacy of a microwave device for treating axillary hyperhidrosis and osmidrosis in Asians: a preliminary study. *J Cosmet Laser Ther* 2013;15(5):255–9. <http://dx.doi.org/10.3109/14764172.2013.807114>.
19. Tronstad C, Helsing P, Tønseth KA, et al. Tumescent suction curettage vs. curettage only for treatment of axillary hyperhidrosis evaluated by subjective and new objective methods. *Acta Derm Venereol* 2013;94(2):215–20. <http://dx.doi.org/10.2340/00015555-1671>.