

- 7 Raynaud F, Leduc C, Anderson WB, Evain-Brion D. Retinoid treatment of human psoriatic fibroblasts induces an increase in cyclic AMP-dependent protein kinase activity. *J Invest Dermatol* 1987; 89: 105-10.
- 8 Raynaud F, Gerbaud P, Enjolras O. A cAMP binding abnormality in psoriasis. *Lancet* 1989; i: 1153-6.
- 9 Iancu L, Shneur A, Cohen H. Trials with xanthine derivatives in systemic treatment of psoriasis. *Dermatologica* 1979; 159: 55-61.
- 10 Man M, Wang F. Treatment of psoriasis with aminophylline. *Int J Dermatol* 1992; 31: 370-1.
- 11 West DP, Fischer JH, Barbour M *et al.* Altered theophylline metabolism in patients with psoriasis. *DICP* 1990; 24: 464-7.

#### No change in skin innervation in patients with palmar hyperhidrosis treated with tap-water iontophoresis

SIR, The cutaneous nerves contain a number of neuropeptides, classical transmitters, and neuron-specific markers.<sup>1-4</sup> The expression of these neuropeptides and neuronal markers alters after tissue injury and inflammation, or during the course of some diseases.<sup>4</sup>

Hyperhidrosis of the palms is a disorder which is socially embarrassing, and interferes with manual occupations. There are several suggested treatments for excessive sweating, including tap-water iontophoresis, which is simple, safe and, in many instances, effective.<sup>5</sup> We have employed indirect immunohistochemistry to investigate whether any changes in the cutaneous nerves and/or cells occur after treatment of palmar hyperhidrosis by iontophoresis.

Five female patients (age range 22-46) suffering from palmar hyperhidrosis were treated by tap-water iontophoresis using a galvanic generator (Drionic, WCT-Medical AB, Partille). The palms were immersed in tap-water in a plastic tray, and a direct current of 30-40 mA was applied for 30 min daily for 12 days (except Saturdays and Sundays). A reduction in sweating was noted between the second and sixth week of treatment. Starch-iodine imprints showed decreased sweating when the pre- and post-treatment samples were compared.

Skin punch biopsy specimens (3 mm diameter) were taken from the hypothenar eminence before the start of treatment and after the twelfth treatment. In addition, skin specimens were taken from four normal healthy volunteers as controls. Lidocaine was used for local anaesthesia. The sections were processed by the indirect immunofluorescence technique,<sup>1,2</sup> using primary substance P (SP), calcitonin gene-related peptide (CGRP), somatostatin (SOM), protein gene product (PGP) 9-5, neuron-specific enolase (NSE), protein S-100 (S-100), vasoactive intestinal polypeptide (VIP), neuropeptide tyrosine (NPY) and tyrosine hydroxylase (TH) antisera.

SP- and CGRP-containing nerves were seen as free nerve terminals in the epidermis, and in the dermis around the secretory coils of the sweat glands, and arterioles, as well as in the Meissner's corpuscles. Numerous VIP, NPY and TH immunoreactive nerves were found innervating the secretory portion of eccrine glands and the arterioles. SOM was present in some small dendritic cells in the dermis. PGP 9-5 and NSE like immunoreactivity was demonstrated in all types of nerves, but the NSE immunofluorescence was of a lesser intensity.

S-100 was demonstrated in dendritic cells in the epidermis, and in the dermis in nerve bundles, around the sweat glands and arterioles, and in the Meissner's corpuscles. There were no obvious differences either between the pre- and post-treatment specimens, or between the pretreatment specimens and the normal healthy skin, with regard to the distribution and morphology of immunoreactive nerves and cells in palmar skin sections incubated with the above antisera.

The mechanism of action of iontophoresis in the therapy of local hyperhidrosis remains unexplained. Hill *et al.*<sup>6</sup> did not find any structural changes in the eccrine glands by light and transmission electron microscopy after tap-water iontophoresis. Local hyperhidrosis of the palms or soles is not a response to heat, but to emotional stimuli, and it is traditionally considered to be a disorder of the autonomic nervous system.

Neuropeptides have been shown to play a role in skin injury, inflammation, and certain diseases. SP induces flare and itch,<sup>7</sup> and SP and CGRP are increased in nodular prurigo.<sup>8</sup> A SOM-containing dendritic cell population in psoriatic skin was discovered to be influenced by peptide T treatment.<sup>9</sup> Anand *et al.*<sup>10</sup> found that VIP was increased in eczema and psoriasis, but they did not see any change of the VIP concentration in skin affected by axillary hyperhidrosis. In the present study, we did not find any change in the innervation density or distribution, on the basis of PGP 9-5 or NSE immunoreactivity; nor was there any alteration of neuropeptide- and/or classical transmitter-containing nerves around the secretory coils of the eccrine glands before and after the treatment, or any influence on the nerves around the arterioles. This implies that hyperhidrosis of the palms is not the result of variations in the neuropeptides mentioned above, or of differences in the innervation of cells in the sweat glands. However, the immunohistochemical method may be unable to detect all possible changes in the neurochemistry of the nerves to the sweat glands or blood vessels in hyperhidrotic states. In addition, we cannot exclude possible changes in other peptide systems. In conclusion, our results show that neither the sympathetic nerves containing VIP, NPY and/or TH, nor the sensory nerves containing SP and/or CGRP are morphologically altered in palmar hyperhidrosis.

#### Acknowledgments

This work was supported by grants from The Swedish Work Environment Fund (project no. 93-0344), Magn. Bergvalls Stiftelse, Edvard Welanders Stiftelse, IngaBritt och Arne Lundbergs Forskningsstiftelse, Torsten och Ragnar Söderbergs Stiftelser, and funds from the Medical Faculty of the Karolinska Institute. Dr Lixin Wang was a recipient of a scholarship from the Wenner-Gren Foundation. We thank Dr S.-W.Han for technical assistance.

Experimental Dermatology Unit,  
Department of Neuroscience,  
Karolinska Institute, Sweden  
\*Department of Dermatology,  
Huddinge Hospital Stockholm,  
Stockholm, Sweden

L.WANG  
M.HILLIGES  
M.GAJECKI\*  
J.A.MARCUSON\*  
O.JOHANSSON

#### Refer

- 1 Jo
- Ir
- an
- 10
- 2 W
- im
- Re
- 3 He
- de
- Ar
- 4 Ta
- ski
- W
- Mc
- 5 De
- 88
- 6 Hi
- ior
- 19
- 7 Hä
- sul
- 8 Mc
- ne
- ch
- 9 Joh
- me
- psc
- 40
- 10 An
- dis
- hy

#### Congee with a

- SIR, A  
abnor  
Howe  
marke  
bulbo  
marke  
other

## References

- 1 Johansson O. Pain, motility, neuropeptides, and the human skin. Immunohistochemical observations. In: *Advances in Pain Research and Therapy* (Tiengo M, Eccles J, Cuello AC, Ottoson D, eds), Vol. 10. New York: Raven Press, 1987; 31-44.
- 2 Wang L, Hilliges M, Jernberg T *et al*. Protein gene product 9.5-immunoreactive nerve fibres and cells in human skin. *Cell Tissue Res* 1990; 261: 25-33.
- 3 Hachisuka H, Mori O, Sakamoto F *et al*. Immunohistological demonstration of S-100 protein in the cutaneous nerve system. *Anat Rec* 1984; 210: 639-46.
- 4 Tausk T, Christian E, Johansson O, Milgram S. Neurobiology of the skin. In: *Dermatology in General Medicine* (Fitzpatrick TB, Eisen AZ, Wolff K, Freedberg IM, Austen KF, eds), 4th edn. New York: McGraw-Hill, 1993; 396-403.
- 5 Dobson RL. Treatment of hyperhidrosis. *Arch Dermatol* 1987; 123: 883-4.
- 6 Hill AC, Baker GF, Jansen GT. Mechanism of action of iontophoresis in the treatment of palmar hyperhidrosis. *Cutis* 1981; 28: 69-72.
- 7 Hägermark Ö, Hökfelt T, Pernow B. Flare and itch induced by substance P in human skin. *J Invest Dermatol* 1978; 71: 233-5.
- 8 Molina FA, Burrows NP, Jones RR *et al*. Increased sensory neuropeptides in nodular prurigo: a quantitative immunohistochemical analysis. *Br J Dermatol* 1992; 127: 344-51.
- 9 Johansson O, Hilliges M, Talme T *et al*. Speculations around the mechanism behind the action of peptide T in the healing of psoriasis: A minireview. *Acta Derm Venereol (Stockh)* 1993; 73: 401-3.
- 10 Anand P, Springall DR, Blank MA *et al*. Neuropeptides in skin disease: increased VIP in eczema and psoriasis but not axillary hyperhidrosis. *Br J Dermatol* 1991; 124: 547-9.

#### Congenital dysmorphism of finger and toenails associated with acro-osteolysis

SIR, A 10-year-old boy presented to our clinic with a history of abnormal nail plates on his fingers and toes since birth. However, the abnormal appearance of his fingernails differed markedly from that of his toenails. There was shortening and bulbous swelling of the ends of the fingers, associated with markedly increased curvature of the nails and pitting, but no other nail plate abnormality (Figs 1 and 2). The fourth fingers

of both hands were spared. In contrast, the toenails were small, thickened, opaque, and yellow (Fig. 3). There was bulbous swelling of the ends of the toes, similar to that seen in the fingers, and this involved all the digits. His nails are slow-growing, and rarely require cutting. His teeth, hair, skin, height, weight and physical and mental development are normal. There is no parental consanguinity, and no other family members have been affected. There is no history of exposure to toxic chemicals, and his mother had not taken any drugs during pregnancy. Serum calcium, phosphate, vitamin D and parathormone levels are normal. Radiographs of the hands and feet show acro-osteolysis, with relative sparing of the third and fourth fingers (Fig. 4). Mycological examination of nail clippings is negative.

Despite similar radiographic changes in this boy's fingers and toes, his nail plates appear to be affected differently. Acro-osteolysis is the occurrence of destructive changes of distal phalangeal bone.<sup>1</sup> It may be idiopathic, when it tends to present in early childhood, or familial. In familial cases males are affected more often than females, and the disorder is associated with a peripheral neuropathy.<sup>2</sup> Pain is a prominent feature of familial acro-osteolysis,<sup>1</sup> but our patient did not complain of any discomfort. Acro-osteolysis may also be secondary to hyperparathyroidism, osteomalacia, occupational exposure to vinyl chloride, psoriatic arthropathy, pyogenic lesions, leprosy, traumatic amputation, vascular lesions, and neuropathy.<sup>2-4</sup> Other rare associations have been claimed, including occupational acro-osteolysis in a professional guitar player.<sup>1</sup>

In the Hajdu-Cheney syndrome acro-osteolysis is associated with a variety of other radiological abnormalities, abnormal facies, and cardiac and neurological abnormalities.<sup>5,6</sup> However, the absence of any family history, lack of other associated features, and the course of our patient's disease do not fit with this diagnosis. Exposure to phenytoin *in utero* may cause hypoplasia of the nails and distal phalanges, associated with other abnormalities, as part of the fetal hydantoin syndrome,<sup>7</sup> but our patient's mother had not taken any drugs during pregnancy. It is possible that this patient has idiopathic acro-osteolysis, or represents a *forme fruste* of the Hajdu-Cheney syndrome. The difference in appearance

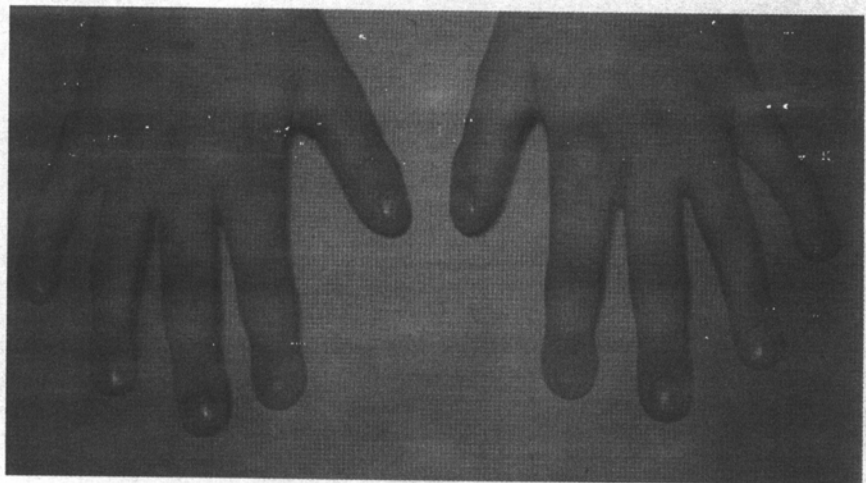


Figure 1. The appearance of the fingers.