
Long-Term Efficacy and Quality of Life in the Treatment of Focal Hyperhidrosis with Botulinum Toxin A

STEPHEN R. TAN, MD AND NOWELL SOLISH, MD, FRCPC

Department of Dermatology, University of Toronto, Toronto, Ontario, Canada

BACKGROUND. Botulinum toxin A has been used increasingly in the treatment of focal hyperhidrosis.

OBJECTIVE. To assess the long-term efficacy of botulinum toxin A in the treatment of hyperhidrosis and the changes in quality of life and patient satisfaction with treatment.

METHODS. A questionnaire was designed to assess the efficacy using visual analog scales and the quality of life both before and after treatment using a modified Dermatology Life Quality Index scale.

RESULTS. There was a reduction in the hyperhidrosis and a statistically significant improvement in the quality of life scores for the axillae, palms, and forehead.

CONCLUSION. Botulinum toxin A injections are safe and effective for the treatment of hyperhidrosis of the axillae, palms, and forehead, resulting in an improved quality of life for patients.

S. R. TAN, MD AND N. SOLISH, MD, FRCPC HAVE INDICATED NO SIGNIFICANT INTEREST WITH COMMERCIAL SUPPORTERS.

Primary hyperhidrosis is a common disorder, estimated to affect 0.6–1.0% of the population.¹ It may be defined as excessive, uncontrollable sweating in the absence of a discernible cause, and is most commonly limited to the axillae, palms, soles, or forehead.^{2,3} The primary, or idiopathic, form of hyperhidrosis may result from a dysregulation of the central sympathetic nervous system, possibly of the hypothalamic nuclei or of the prefrontal areas and their connections.^{2,4} Localized hyperhidrosis is most commonly primary, but may occur secondary to olfactory or gustatory stimuli, intrathoracic neoplasms, neurologic lesions, and Frey's syndrome.¹ In addition, palmoplantar hyperhidrosis may occur in some patients with Raynaud's disease, rheumatoid arthritis, erythromelalgia, nail patella syndrome, keratosis palmaris et plantaris, atrioventricular fistula, and cold injury.¹

Several therapies are currently available for the treatment of focal hyperhidrosis. Topical aluminum chloride and iontophoresis may be effective, possibly through mechanical obstruction of eccrine sweat gland pores; however, both of these modalities give short-term benefit.^{1,5} Systemic anticholinergic agents have been used, but the dosage required to achieve a reduction in sweating commonly has significant side effects.¹ A direct surgical approach is the excision of

the area of sweating, which may be appropriate if the area of excessive sweating is small.¹ Sympathectomy has been used with success, but carries significant risks, including the development of compensatory hyperhidrosis in other areas of the body.^{1,6} Finally, liposuction has been advocated as an effective treatment option, with the intent of removing eccrine sweat glands from the junction of the dermis and the subcutaneous tissue.^{7,8}

Botulinum Toxin and Hyperhidrosis

Botulinum toxins are a family of neurotoxins produced by the anaerobic bacterium *Clostridium botulinum*, and botulinum toxin A has been used in clinical medicine for several applications.⁹ The medical applications were first hypothesized by Justinus Kerner around 1820 in his description of food-borne botulism.¹⁰ Botulinum toxin A acts by blocking the release of acetylcholine from the presynaptic terminal of the neuromuscular junction.¹¹ Nerve fiber degeneration and sweat gland atrophy do not appear to be major components of botulinum toxin action.¹² Botulinum toxin A is available in two preparations: in the United States, it is available as Botox (manufactured by Allergan, Irvine, CA) and in Europe as Botox or Dysport (manufactured by Ipsen Biopharm, Wrexham, UK). In terms of efficacy, one unit of Botox is estimated to be equal to 3–5 U of Dysport.¹³

As the innervation at both the neuromuscular junction and the eccrine sweat glands utilize acetylcholine as the neurotransmitter, botulinum toxin A has been

Address correspondence and reprint requests to: Nowell Solish, MD, 76 Grenville St., Room 841, Toronto, Ontario M5S 1B2, Canada, or e-mail: n.solish@utoronto.ca.

used in dermatology in the treatment of hyperfunctional facial lines and of focal hyperhidrosis. When injected intradermally into the forearm of a normal control, 0.1–1.0 U of Botox produces a 1.0–1.5 cm² anhidrotic area.¹⁴ When used for hyperhidrosis, a 5–10 U injection of Botox produces an anhidrotic area of 1.2–1.9 cm² within 6 days.¹⁵ After 6 months, the anhidrotic skin area decreases, suggesting partial recovery of sweat gland function.¹⁶ The extent of the anhidrotic effect of botulinum toxin A is dose dependent, with a minimum dose of 2.5 U/cm² of Dysport (approximately 0.625 U of Botox) needed to obtain an effect on sweat production.¹⁶ To block sweat gland activity completely, 20 U/cm² of Dysport (approximately 5 U of Botox) are needed.¹⁶

In several trials, botulinum toxin A has been shown to be effective in reducing axillary hyperhidrosis, with the average relapse occurring after 4–6 months.^{15,17–20} The degree of reduction in sweat has been confirmed by gravimetric measurement.¹⁷ There appears to be a dose-response relationship, with higher doses of botulinum toxin A producing longer remissions of up to 7–15 months.¹⁵ Botulinum toxin A has been shown to be effective in the treatment of palmar hyperhidrosis, with the reduction in sweating reported to last from 2 to 12 months.^{21–25} In the treatment of forehead hyperhidrosis, botulinum toxin A has been shown to significantly reduce the amount of sweating for at least 5 months.³ Botulinum toxin A has also been shown to be effective in treating focal hyperhidrosis associated with Frey's syndrome.^{26,27}

Moderate to severe localized hyperhidrosis is associated with considerable morbidity, including skin maceration, secondary microbial infection, soiling of clothing, social embarrassment, and occupational disability.^{1,17} The present study was undertaken to evaluate the patient's perception of the efficacy of botulinum toxin A in the treatment of focal hyperhidrosis, as well as to assess any noted changes in the quality of life as a result of the botulinum toxin A treatment.

Materials and Methods

This study was reviewed and approved by the Research Ethics Board of the University of Toronto and informed consent was obtained from all subjects. The study was designed as a retrospective analysis of patients treated for hyperhidrosis with botulinum toxin A over the past 3 years. In all cases, the form of botulinum toxin A used was Botox. For the treatment of the axillae or the palms, a total of 100 U of botulinum toxin A were injected. To evenly cover the focal hyperhidrosis within these areas, a Minor starch iodine test was performed prior to treatment, and 50 U of Botox were injected evenly throughout the affected area on each side. In the case of forehead injections for hyperhidrosis, up to 100

U of botulinum toxin A were injected into the hyperhidrotic areas of the forehead identified with the Minor starch iodine test. In all cases, each injection was placed in the dermis or in the dermosubcutaneous fat junction.

A follow-up questionnaire was designed to assess several parameters, including the age of onset and noticeability of the sweating at that time, the subjective efficacy of the botulinum toxin A treatment at various time intervals, the time at which the patient felt the sweating had returned sufficiently to warrant a re-treatment and the level of sweating at that time, and the patient's assessment of their quality of life before and after the botulinum toxin A treatment. In addition, the patients were asked to elaborate on any complications they experienced as a result of the treatment and to comment on any additional impacts that the botulinum toxin A treatment had on their lives.

Visual analog scores were utilized to assess parameters such as the noticeability of the sweating and patient satisfaction. Each visual analog score scale was drawn along a 100 mm line, with opposite descriptions at either end of the line. To assess the quality of life, a modified Dermatology Life Quality Index was developed (Figure 1). The questionnaire was modified from the standard questionnaire, changing the wording in question 1 from "symptomatic" to "sweaty," to make it more appropriate for application in hyperhidrosis. The Dermatology Life Quality Index questionnaire used in this study was scored in the standard fashion.²⁸

Statistical analysis was performed using the paired Students *t*-test, comparing the individual and the total Dermatology Life Quality Index scores before and after the botulinum toxin A treatment. All statistical analyses were two-sided, with an α -error of 0.05.

Results

A total of 58 people were approached to complete the survey, of which 34 agreed to participate in the study. Of the 58 surveys mailed out, 10 people had changed addresses and could not be located, 2 people contacted us and refused to participate, and the remaining 12 did not respond to the survey. The demographics of the study are shown in Table 1. The average age at onset of the hyperhidrosis was 15.6 ± 8.4 years, and the noticeability of the hyperhidrosis at onset for all locations was rated as 92.7 ± 10.9 on a visual analog scale.

The perceived effectiveness of botulinum toxin A is shown in Figure 2 for axillae, palms, and forehead. The timing and degree of symptoms at the return of hyperhidrosis are shown in Table 2. The average maximal effect for the axillary treatments was approximately 80%, which was reached in 2 weeks–3 months and lasted for almost 6 months before a re-treatment was required. Similarly the palms reached an average maximal effect of approximately 53% in 2 weeks, and this effect gradually tapered off over the next 6 months. The forehead responded very well, with an

Before the BOTOX treatment, how sweaty had your skin been?	Very much A lot A little Not at all	
Before the BOTOX treatment, how embarrassed or self-conscious had you been because of your skin?	Very much A lot A little Not at all	
Before the BOTOX treatment, how much had your skin interfered with you going shopping or looking after your home or garden ?	Very much A lot A little Not at all	Not relevant
Before the BOTOX treatment, how much had your skin influenced the clothes you wear?	Very much A lot A little Not at all	Not relevant
Before the BOTOX treatment, how much had your skin affected any social or leisure activities?	Very much A lot A little Not at all	Not relevant
Before the BOTOX treatment, how much had your skin made it difficult for you to do any sport ?	Very much A lot A little Not at all	Not relevant
Before the BOTOX treatment, had your skin prevented you from working or studying ?	Yes No	Not relevant
a. If "no", before the BOTOX treatment, how much had your skin been a problem at work or studying ?	A lot A little Not at all	
Before the BOTOX treatment, how much had your skin created problems with your partner or any of your close friends or relatives ?	Very much A lot A little Not at all	Not relevant
Before the BOTOX treatment, how much had your skin caused any sexual difficulties ?	Very much A lot A little Not at all	Not relevant
Before the BOTOX treatment, how much of a problem had the treatment for your skin been, for example by being messy or by taking up time?	Very much A lot A little Not at all	Not relevant

Figure 1. Modified Dermatology Life Quality Index for hyperhidrosis.

average maximum rated efficacy of 100% within 2 weeks. The effect gradually tapered off, with a desired re-treatment after 4.5 months.

The total Dermatology Life Quality Index scores for before and after the botulinum toxin A injections are shown in Figure 3. The difference in the Dermatology Life Quality Index score before and after botulinum toxin A therapy was statistically significant for the axillae ($P < .001$), the palms ($P < .02$), and the forehead ($P < .03$). Overall patient satisfaction with

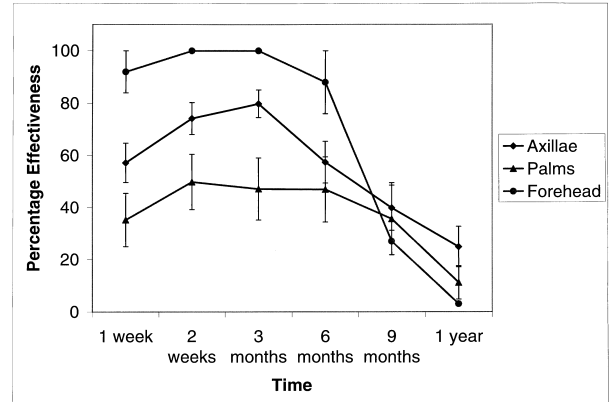


Figure 2. Efficacy of botulinum toxin A for hyperhidrosis of the axillae, forehead, and palms (average \pm standard error of the mean).

the botulinum toxin A injections in the therapy of hyperhidrosis is shown in Figure 4.

For the comments on the actual injections, most patients only noted mild pain at the injection sites; notably the pain was greatest for injections into the palms, as shown in Table 3. Also, 3 of the 10 patients treated for palmar hyperhidrosis noted a transient, mild weakness in their hands. One patient who had treatment of the axillae noted an increase in sweating over the forehead, which this person found particularly troublesome. Finally, one patient treated with forehead injections noted that he was unable to wrinkle his forehead well after the injections.

Discussion

In this study, botulinum toxin A injections proved to be an effective method for treating focal hyperhidrosis. The durations of effect are similar to the durations noted in previous studies. Notably the treatments of the axillae, forehead, and palms all had good remission, lasting on average between 4 and 7 months.

As in previous studies, patients treated with botulinum toxin A for palmar hyperhidrosis had a variable duration of response. Although the average suppression of hyperhidrosis lasted for more than 6 months, there was a wide range; some patients had very lengthy remission for more than 1 year, while others

Table 1. Study Demographics

Total	34
Axillary	22
Forehead	2
Palms	10
Age (years)	29.6 (range 17–56)
Gender	21 female, 13 male

Table 2. Timing and Degree of Symptoms at Return (Average \pm Standard Deviation)

Location	Time of return of symptoms (months)	Visual analog score rating severity of hyperhidrosis
Axillary	5.9 \pm 3.2	72.3 \pm 21.8
Forehead	4.5 \pm 0	57.0 \pm 0
Palms	7.7 \pm 5.0	84.3 \pm 22.8

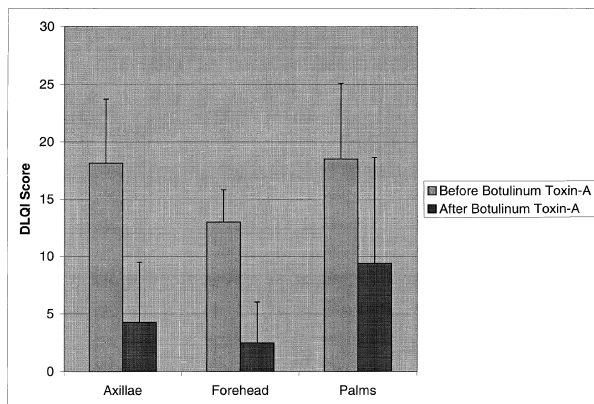


Figure 3. Dermatology Life Quality Index total scores (average \pm standard deviation).

had a very short duration of effect. Notably this retrospective study reflected our previous protocol for palmar hyperhidrosis, which involved injecting 50 U into the palms only. We have subsequently changed the protocol, and we currently inject 100 U into each palm and the affected areas of the fingers, for a total dose of 200 U. With this increased dose injected over the entire palmar surface of the hands, we hope to achieve better suppression and longer remissions of palmar hyperhidrosis.

The Dermatology Life Quality Index is a validated tool for measuring the impact of cutaneous disease on the quality of life of patients and it has been applied to many common skin conditions, such as psoriasis and atopic dermatitis. To our knowledge, the Dermatology Life Quality Index has not previously been used to assess the change in quality of life with the treatment of hyperhidrosis with botulinum toxin A. In this study, there was a statistically significant improvement in the Dermatology Life Quality Index for pa-

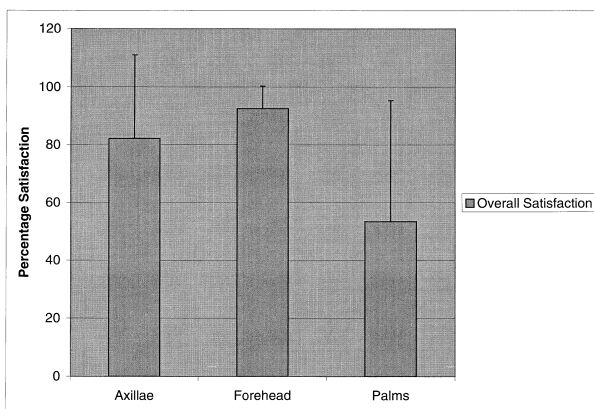


Figure 4. Overall patient satisfaction with botulinum toxin A for the treatment of hyperhidrosis (average \pm standard deviation).

Table 3. Visual Analog Scores of Pain During the Botulinum Toxin A Injections (Average \pm Standard Deviation)

Location	Pain during treatment
Axillary	29.9 \pm 24.5
Forehead	35.5 \pm 47.4
Palms	68.1 \pm 31.8

tients treated with botulinum toxin A for hyperhidrosis of the axillae, palms, and forehead. This was reflected in the positive patient comments and the relatively high overall patient satisfaction ratings for these areas.

The side effects seen with botulinum toxin A treatment, specifically pain with injections and mild weakness of the hands after palmar injections, are consistent with the current literature. Notably the pain was rated as significantly greater for injections into the palms, possibly because of the increased thickness of the skin and the multiple sensory receptors at this location. The complication of compensatory hyperhidrosis on the face noted by one patient treated for axillary hyperhidrosis has not been reported previously with botulinum toxin A treatments. This may reflect a physiologic response in times of thermal stress, with a compensatory increase in sweating in other areas to compensate for the decrease in axillary sweating. Alternatively, this may reflect a subjective perception of an increase in sweating in this area, which may not have seemed to be as severe compared to the axillary area prior to treatment. This interesting side effect may be seen more frequently, as botulinum toxin A is increasingly used in the treatment of hyperhidrosis.

For comments on the changes in their quality of life, many patients noted a decrease in self-consciousness and an improvement in their self-confidence. With axillary hyperhidrosis, patients specifically noted that they were able to change their wardrobe and to wear multiple colors, as opposed to simply black, which does not show the sweat stains. Also, several people said that they had previously dressed lightly, even in cold weather, in the hope that this would help to decrease the axillary hyperhidrosis; after treatment, this practice was no longer necessary. Patients with palmar hyperhidrosis commented that they noted improvements when they had to shake people's hands, especially those patients involved with any type of public relations. Finally, one dramatic patient said that she had been on the verge of suicide as the hyperhidrosis had completely disrupted her life, and that these feelings had subsided as the hyperhidrosis improved after the botulinum toxin A injections.

One potential weakness of this study is the small number of patients in the group treated for forehead

hyperhidrosis. This reflects the distribution of patients seen in this practice, with the majority being treated for axillary and palmar hyperhidrosis. In the future, data should continue to be collected in all of these areas to further our knowledge of the treatment of hyperhidrosis with botulinum toxin A.

In conclusion, botulinum toxin A injections are a safe and effective treatment for hyperhidrosis of the axillae, palms, and forehead, resulting in significant improvement in the quality of life for the treated patients.

Acknowledgment This work was carried out in the Department of Dermatology, Sunnybrook and Women's College Health Science Center, affiliated with the University of Toronto.

References

1. Stolman LP. Treatment of hyperhidrosis. *Dermatol Clin* 1998;16:863-7.
2. Sato K, Kang WH, Saga K, Sato KT. Biology of sweat glands and their disorders. II. Disorders of sweat gland function. *J Am Acad Dermatol* 1989;20:713-26.
3. Kinkelin I, Hund M, Naumann M, Hamm H. Effective treatment of frontal hyperhidrosis with botulinum toxin A. *Br J Dermatol* 2000;143:824-7.
4. Sato K, Kang WH, Saga K, Sato KT. Biology of sweat glands and their disorders. I. Normal sweat gland function. *J Am Acad Dermatol* 1989;20:537-63.
5. Schnider P, Binder M, Berger T, Auff E. Botulinum A toxin injection in focal hyperhidrosis. *Br J Dermatol* 1996;134:1160-1.
6. Herbst F, Plas EG, Fugger R, Fritsch A. Endoscopic thoracic sympathectomy for primary hyperhidrosis of the upper limbs: a critical analysis and long-term results of 480 operations. *Ann Surg* 1994;220:86-90.
7. Shenaq SM, Spira M, Christ J. Treatment of bilateral axillary hyperhidrosis by suction-assisted lipolysis technique. *Ann Plast Surg* 1987;19:548-51.
8. Swinehart JM. Treatment of axillary hyperhidrosis: combination of the starch-iodine test with the tumescent liposuction technique. *Dermatol Surg* 2000;26:392-6.
9. Boni R, Kreyden OP, Burg G. Revival of the use of botulinum toxin: application in dermatology. *Dermatology* 2000;200:287-91.
10. Erbguth FJ, Naumann M. Historical aspects of botulinum toxin: Justinus Kerner (1786-1862) and the "sausage poison." *Neurology* 1999;53:1850-53.
11. Huang W, Foster JA, Rogachefsky AS. Pharmacology of botulinum toxin. *J Am Acad Dermatol* 2000;43:249-59.
12. Naumann M, Hofmann U, Bergmann I, Hamm H, Toyka K, Reiners K. Focal hyperhidrosis: effective treatment with intracutaneous botulinum toxin. *Arch Dermatol* 1998;134:301-4.
13. Brin MF. Botulinum toxin: chemistry, pharmacology, toxicity, and immunology. *Muscle Nerve Suppl* 1997;6:S146-68.
14. Cheshire WP. Subcutaneous botulinum toxin type A inhibits regional sweating: an individual observation. *Clin Auton Res* 1996;6:123-4.
15. Karamfilov T, Konrad H, Karte K, Wollina U. Lower relapse rate of botulinum toxin A therapy for axillary hyperhidrosis by dose increase. *Arch Dermatol* 2000;136:487-90.
16. Braune C, Erbguth F, Birklein F. Dose thresholds and duration of the local anhidrotic effect of botulinum toxin injections: measured by sudometry. *Br J Dermatol* 2001;144:111-7.
17. Heckmann M, Ceballos-Baumann AO, Plewig G. Botulinum toxin A for axillary hyperhidrosis (excessive sweating). *N Engl J Med* 2001;344:488-93.
18. Schnider P, Binder M, Kittler H, et al. A randomized, double-blind, placebo-controlled trial of botulinum A toxin for severe axillary hyperhidrosis. *Br J Dermatol* 1999;140:677-80.
19. Heckmann M, Breit S, Ceballos-Baumann A, Schaller M, Plewig G. Side-controlled intradermal injection of botulinum toxin A in recalcitrant axillary hyperhidrosis. *J Am Acad Dermatol* 1999;41:987-90.
20. Glogau RG. Botulinum A neurotoxin for axillary hyperhidrosis: no sweat Botox. *Dermatol Surg* 1998;24:817-9.
21. Schnider P, Binder M, Auff E, Kittler H, Berger T, Wolff K. Double-blind trial of botulinum A toxin for the treatment of focal hyperhidrosis of the palms. *Br J Dermatol* 1997;136:548-52.
22. Shelley WB, Talanin NY, Shelley ED. Botulinum toxin therapy for palmar hyperhidrosis. *J Am Acad Dermatol* 1998;38:227-9.
23. Schnider P, Binder M, Kittler H, Steinhoff N, Auff E. Uses of botulinum toxin. *Lancet* 1997;349:953.
24. Naumann M, Flachenecker P, Brocker EB, Toyka KV, Reiners K. Botulinum toxin for palmar hyperhidrosis. *Lancet* 1997;349:252.
25. Solomon B, Hayman R. Botulinum toxin type A therapy for palmar and digital hyperhidrosis. *J Am Acad Dermatol* 2000;42:1026-9.
26. Birch JF, Varma SK, Narula AA. Botulinum toxoid in the management of gustatory sweating (Frey's syndrome) after superficial parotidectomy. *Br J Plast Surg* 1999;52:230-31.
27. Von Lindern JJ, Niederhagen B, Berge S, Hagler G, Reich RH. Frey syndrome: treatment with type A botulinum toxin. *Cancer* 2000;89:1659-63.
28. Finlay AY, Khan GK. Dermatology Life Quality Index (DLQI)—a simple practical measure for routine clinical use. *Clin Exp Dermatol* 1994;19:210-16.