

Case report

Compensatory hyperhidrosis: a consequence of truncal sympathectomy treated by video assisted application of botulinum toxin and reoperation

Christopher Andrew Efthymiou, James Andrew Charles Thorpe*

Department of Thoracic Surgery, St James' Hospital, Beckett Street, Leeds, LS9 7TF, United Kingdom

Received 8 February 2008; received in revised form 9 March 2008; accepted 11 March 2008

Abstract

Hyperhidrosis is a debilitating condition characterised by sweating that exceeds the need of normal thermoregulation. Surgical management of primary hyperhidrosis by upper dorsal sympathectomy is the treatment of choice for intractable hyperhidrosis, however, paradoxically it may be followed by troublesome compensatory hyperhidrosis in a significant number of patients. The frequency of compensatory hyperhidrosis often reflects the extensiveness of the denervation. We report for the first time the successful treatment of a patient who developed compensatory hyperhidrosis following sympathectomy using video assisted extension of the sympathectomy by application of botulinum toxin (BTX-A). In addition, this case highlights the use of botulinum toxin as a guide for the potential successful management of compensatory hyperhidrosis prior to definitive extension of a sympathectomy.

© 2008 European Association for Cardio-Thoracic Surgery. Published by Elsevier B.V. All rights reserved.

Keywords: Palmar axillary hyperhidrosis; Compensatory sweating; BTX-A botox; Sympathectomy

1. Introduction

Hyperhidrosis is characterised by excessive sweating that may be generalised or confined to the hands, axillae, face or feet. The incidence of hyperhidrosis is uncertain but the prevalence in young men is 0.6–1% for palmar hyperhidrosis; familial involvement being reported in 25% of patients [1].

Sufferers of this debilitating illness are frequently embarrassed by their 'wet' handshake and sweat stained clothes, often leading to significant psychological and social morbidity.

Treatment initially consists of topical applications of antiperspirants containing aluminium salts, tanning agents, and iontophoresis with water or anticholinergic solution. Anxiolytic drugs are also frequently prescribed, however, their value is doubtful and there is a risk of inducing dependency. Anticholinergics such as propantheline bromide have shown effectiveness. However, in therapeutic doses these cause unpleasant side effects such as drowsiness, dry mouth, dilated pupils, and constipation. Thus, many patients are forced to discontinue this management.

In view of the varying levels of success offered by these treatments the definitive treatment for axillary and palmar hyperhidrosis is sympathectomy in which destruction of the T2 and T3 ganglia is performed (Fig. 1).

Despite the efficacy with which bilateral T2 and T3 sympathectomy can treat hyperhidrosis, it is known that

troublesome compensatory hyperhidrosis with excessive sweating over the trunk and upper thorax can occur in up to 75% of patients. Most patients however, find this less objectionable than axillary and palmar hyperhidrosis [2].

2. Case report

We report a case of a 32-year-old male, originally referred for treatment of severe axillary and palmar hyperhidrosis and facial flushing. The patient had failed to respond to medical therapy with propantheline and propranolol, and was therefore considered for surgical management. Initial surgery consisted of bilateral video assisted (VATS) sympathectomy. The patient was intubated with a double lumen tube and positioned for a lateral thoracotomy with the arm elevation and subsequent repositioning of the patient for the contra-lateral operation. Two (20 mm flexipath) ports were placed in the axillary avenue and the sympathetic trunk was located and divided above the T2 ganglion down to below the T4 ganglion.

The early postoperative response was favourable, with the patient experiencing dry hands and axillae. Within 6 weeks however, the patient began to note severe symptoms of compensatory hyperhidrosis on both his trunk and legs, which prevented him from returning to work as a swimming coach.

Initial treatment of the patient's compensatory hyperhidrosis consisted of recommencing medical therapy with propantheline and propranolol. Unfortunately, this did not

* Corresponding author. Tel.: +44 113 3925 737; fax: +44 113 3926 657.
E-mail address: thorpyat@aol.com (J.A.C. Thorpe).

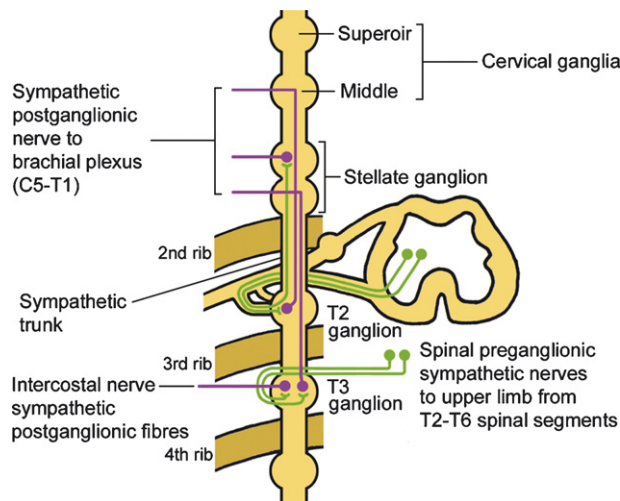


Fig. 1. Sympathetic nerve supply to the upper limb and axilla. It can be seen that interruption of all the sympathetic nerve supply to the upper limb can be achieved by division of the sympathetic trunk between the first and second thoracic sympathetic ganglia. Sympathectomy of the axilla requires the ablation of the second and third thoracic sympathetic ganglia.

alleviate the symptoms. It was therefore considered that in light of the recent successful reports of the use of botulinum toxin type-A (BTX-A) for the treatment of axillary hyperhidrosis by subcutaneous injection [3], that the direct injection of the neurotoxin into the sympathetic chain below the sympathectomy could possibly cure these undesired symptoms.

Using an identical VATS approach with utilisation of the previous port sites, uneventful access to the sympathetic chain was obtained and BTX-A was injected bilaterally to both the intercostal and sympathetic ganglia from T4 to T6 (100 units per side). Recovery was unremarkable and postoperative results were extremely encouraging. The patient demonstrated a significant reduction of his symptoms on both his trunk and legs. Despite a dramatic improvement in the patient's symptoms the benefits were predominately unilateral, with some residual sweating on the left lower leg. The patient once again sought the possibility of further intervention.

He was therefore considered for an extended bilateral sympathectomy (T4–T6) 12 months after his initial sympathectomy. The procedure was performed with the patient in the lateral thoracotomy position and using the previous thoracoscopic ports. Minimal adhesions were encountered and divided using diathermy. The sympathectomy was then extended from T4 to T6 following which complete resolution of his symptoms of compensatory hyperhidrosis was noted. At follow-up clinic the patient confirmed no further issues with axillary or palmar hyperhidrosis, and was no longer troubled with compensatory hyperhidrosis.

3. Discussion

This case confirms the difficult nature of treating hyperhidrosis, and the impact severe hyperhidrosis has on an individual's quality of life. Thoracic sympathectomy, by interruption of the transmission of impulses from sympathetic ganglia to the sweat glands offers a permanent cure for axillary and palmar hyperhidrosis. Compensatory sweating

appears to be a relatively common side effect following sympathectomy; its rate of occurrence in some series ranges from 60 to 90% [4–7].

A group of 265 patients followed-up post sympathectomy showed that the time course for compensatory hyperhidrosis appeared to be a dynamic phenomenon [8]. Fifty percent of patients developed it immediately following surgery, 80% after 3 months and 90% after 6 months. It was also noted that the severity of compensatory hyperhidrosis did not change with time in the majority of patients (70%), but increased in severity in 10% of patients and decreased in severity in 20% within 2 years of surgery.

Furthermore the mechanisms of compensatory hyperhidrosis have not been fully elucidated and it is debated whether or not the extent of a sympathetic resection leads to a higher or lower risk of this complication [1,9].

Our case is the first to report the use of endoscopic administration of botulinum toxin to the sympathetic chain to relieve symptoms of compensatory hyperhidrosis used in combination with T4–T6 sympathectomy.

To conclude, the use of endoscopic sympathectomy for the treatment of palmar and axillary hyperhidrosis is considered an effective treatment for this condition. However, compensatory sweating is the main limitation of sympathetic chain surgery. The use of botulinum toxin for the treatment of hyperhidrosis was first demonstrated in 1996 as a treatment for axillary hyperhidrosis. In this study, subcutaneous injections of botulinum toxin were found to selectively denervate the local sweat glands producing an anhidrotic patch [10].

This case demonstrates the successful treatment of compensatory hyperhidrosis using endoscopically administered botulinum toxin to the sympathetic chain, and thus confirms this therapy as an efficient adjunct to sympathectomy should this troublesome side effect occur.

References

- [1] Adar R. Surgical treatment of palmar hyperhidrosis before thoracoscopy: experience with 475 patients. *Eur J Surg Suppl* 1994;(572):9–11.
- [2] Sato K, Kang WH, Saga K, Sato KT. Biology of sweat glands and their disorders. I. Normal sweat gland function. *J Am Acad Dermatol* 1989;20(4):537–63.
- [3] Naumann M, Lowe NJ, Kumar CR, Hamm H, Hyperhidrosis Clinical Investigators Group. Botulinum toxin type a is a safe and effective treatment for axillary hyperhidrosis over 16 months: a prospective study. *Arch Dermatol* 2003;139(6):731–6.
- [4] Dumont P, Denoyer A, Robin P. Long-term results of thoracoscopic sympathectomy for hyperhidrosis. *Ann Thorac Surg* 2004;78(5):1801–7.
- [5] Lin TS, Wang NP, Huang LC. Pitfalls and complication avoidance associated with transthoracic endoscopic sympathectomy for primary hyperhidrosis (analysis of 2200 cases). *Int J Surg Investig* 2001;2(5):377–85.
- [6] Zacherl J, Huber ER, Imhof M, Plas EG, Herbst F, Függer R. Long-term results of 630 thoracoscopic sympathectomies for primary hyperhidrosis: the Vienna experience. *Eur J Surg Suppl* 1998;(580):43–6.
- [7] Licht PB, Pilegaard HK. Severity of compensatory sweating after thoracoscopic sympathectomy. *Ann Thorac Surg* 2004;78(2):427–31.
- [8] Steiner Z, Kleiner O, Hershkovitz Y, Mogilner J, Cohen Z. Compensatory sweating after thoracoscopic sympathectomy: an acceptable trade-off. *J Pediatr Surg* 2007;42(7):1238–42.
- [9] Gjerris F, Olesen HP. Palmar hyperhidrosis. Long-term results following high thoracic sympathectomy. *Acta Neurol Scand* 1975;51(2):167–72.
- [10] Bushara KO, Park DM, Jones JC, Schutta HS. Botulinum toxin—a possible new treatment for axillary hyperhidrosis. *Clin Exp Dermatol* 1996;21(4):276–8.