


# Treatment of Compensatory Hyperhidrosis With Botulinum Toxin Type A

LT Eric E. Belin, MC, USN; CDR James Polo, MC, USN

*Compensatory hyperhidrosis is a common and potentially severe side effect of bilateral endoscopic thoracic sympathectomy. We describe a patient with severe compensatory hyperhidrosis as a result of this procedure. We treated the patient with 2 separate series of subcutaneous botulinum toxin type A injections to the right upper abdomen and achieved anhidrosis in 5 weeks. Although botulinum toxin is already an established treatment modality for primary hyperhidrosis, there is little experience using it for the treatment of compensatory hyperhidrosis. Because of its efficacy and low side-effect profile, we believe botulinum toxin may play a significant role in treating compensatory hyperhidrosis as a first-line agent.*

## Case Report

We present a 20-year-old white man on active duty in the US Navy with a 5-year history of hyperhidrosis, primarily on the axilla. Because of his excessive perspiration, the patient was forced to change his uniform several times a day to maintain a clean appearance. This proved both expensive and embarrassing and led him to seek treatment. After evaluation by a cardiothoracic surgeon, the patient elected to undergo bilateral endoscopic thoracic sympathectomy. The procedure involved complete transection of the T2 to T4 ganglia bilaterally. As expected, facial and axillary anhidrosis developed; however, within one month, the patient began to complain of significantly increased perspiration from the nipple line down to his knees (Figure 1). The surgeon who performed the operation had little to offer the patient, who eventually sought treatment in the neurology



**Figure 1.** Patient exhibits severe perspiration after only a few minutes of walking.

Accepted for publication July 19, 2002.

Dr. Belin is from the United States Naval Academy, Annapolis, Maryland. Dr. Polo is from Camp Lejeune Naval Hospital, North Carolina.

The views expressed in this article are those of the authors and do not reflect the official policy or position of the US Navy, US Department of Defense, or the United States government. Reprints: LT Eric E. Belin, 250 Wood Rd, Annapolis, MD 21402-5050.

clinic. After initial evaluation by a neurologist, the patient was referred to the dermatology clinic, where we assumed care. We elected to treat the patient with botulinum toxin type A (Botox®). The botulinum toxin was reconstituted to a concentration of 2 units per 0.1 mL and 48 separate injections of 0.1 mL were placed subcutaneously, 1-cm apart, to the patient's right upper abdomen (Figure 2). The patient returned to the clinic in 3 weeks, at which time an iodine starch test (Minor sweat test) demonstrated a small but appreciable decrease in perspiration. A second treatment was then administered with a stronger con-



Figure 2. Placement of the initial treatment series.

centration of botulinum toxin at 4 units per 0.1 mL.

Twenty-three injections were placed 1-cm apart, slightly more inferior and medial to the initial area treated. At the 2-week follow-up, the patient demonstrated a complete cessation of perspiration in each of the treated areas (Figure 3).

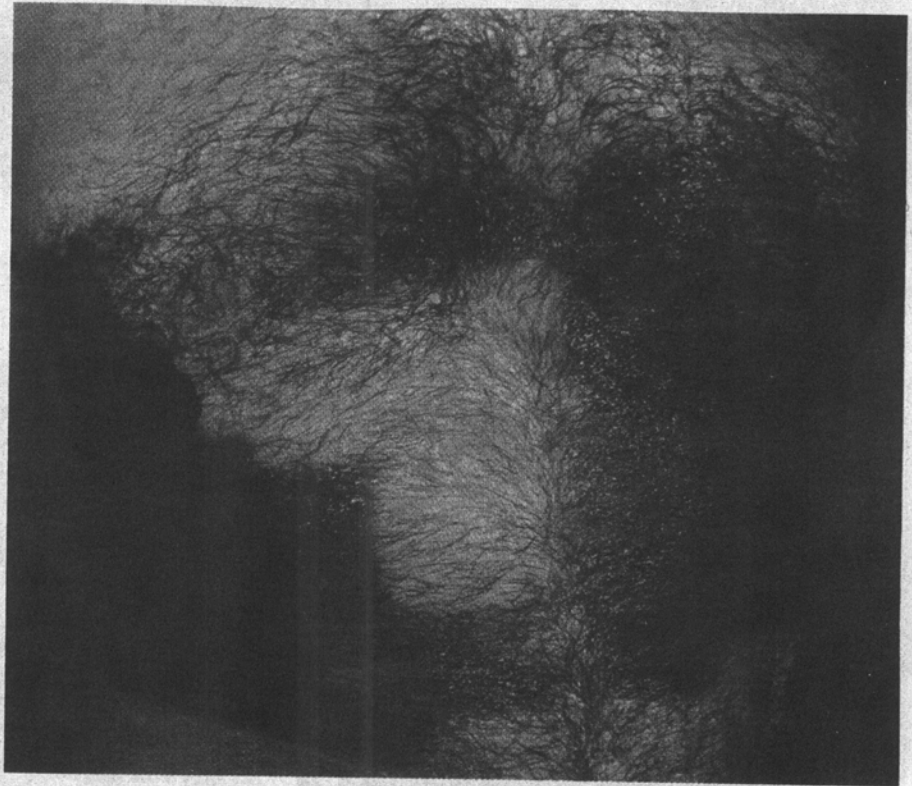
### Comment

Hyperhidrosis can be defined as sweating beyond what is needed to maintain a body's thermal regulation.<sup>1</sup> Axillary hyperhidrosis is often socially embarrassing, and for some individuals the condition may limit occupational pursuit. Axillary hyperhidrosis is usually treatable by conservative measures including topical application of drying agents such as 25% aluminum chloride.<sup>2</sup> Other treatment modalities include local excision of the sweat glands and endoscopic thoracic sympathectomy.<sup>1</sup> Sympathectomy usually produces axillary anhidrosis; however, it is not without considerable risk. Some of the reported complications include gustatory sweating, Horner's syndrome, hemothorax, intercostal neuralgia, recurrence of hyperhidrosis, and most commonly, compensatory hyperhidrosis to an area not previously affected.<sup>1,3</sup> Occurrence rates for compensatory hyperhidrosis vary widely. Some studies claim the rates are as low as 24%, while others claim an occurrence of nearly

100%.<sup>1,3,4</sup> Furthermore, anywhere from 2% to 43% of patients who experience compensatory hyperhidrosis claim that this new condition is much more severe and debilitating than the condition for which they initially sought treatment.<sup>1,3,4</sup>

More recently, botulinum toxin has been used with considerable success in treating axillary hyperhidrosis. Botulinum toxin was first approved by the US Food and Drug Administration in 1989 for use in treating strabismus, blepharospasm, and hemifacial spasm.<sup>5</sup> Additionally, clinicians have found other dermatologic uses for botulinum toxin, including elimination of glabellar furrows and lateral canthal rhytids,<sup>5</sup> and most recently, treatment of idiopathic localized unilateral hyperhidrosis.<sup>6</sup> The success of botulinum toxin in treating axillary hyperhidrosis is becoming well established. It acts by blocking the release of acetylcholine from overactive cholinergic sudomotor nerve fibers, which innervate eccrine sweat glands.<sup>7</sup> In addition to being quite efficacious, botulinum toxin has a lower side-effect profile, with only 5% of patients treated developing compensatory hyperhidrosis.<sup>7</sup>

Although botulinum toxin has proven useful in treating primary hyperhidrosis, very little has been written concerning its possible benefit in controlling compensatory hyperhidrosis. We achieved an excellent response in our patient with only 2 treatments.



**Figure 3.** Minor sweat test reveals complete anhidrosis following the second treatment series.

Of note, the second treatment site had minimal overlap with the first; yet, at the final follow-up, both sites showed near complete anhidrosis. This suggests that one injection may be sufficient, and the lower initial dose simply required more time to take effect.

Although botulinum toxin treatments will not provide a complete solution for this patient because of the surface area involved, they may be quite useful in patients whose compensatory hyperhidrosis involves small areas of the body. Our review of the literature and our own experience in using botulinum toxin suggests that this modality holds significant promise as a safe and effective means of treating both primary and compensatory hyperhidrosis and should be given consideration as a first-line treatment option.

#### REFERENCES

1. Stolman LP. Treatment of hyperhidrosis. *Dermatol Clin.* 1998;16:863-869.

2. Goldsmith L. Disorders of the eccrine sweat gland. In: Fitzpatrick TB, Eisen AZ, Wolff K, et al, eds. *Dermatology in General Medicine.* 5th ed. Vol 1. New York, NY: McGraw-Hill, Inc; 1999:800-809.
3. Drott C, Gothberg G, Claes G. Endoscopic transthoracic sympathectomy: an efficient and safe method for the treatment of hyperhidrosis. *J Am Acad Dermatol.* 1995;33:78-81.
4. Hsu CP, Shia SE, Hsia JY, et al. Experiences in thoracoscopic sympathectomy for axillary hyperhidrosis and osmidrosis: focusing on the extent of sympathectomy. *Arch Surg.* 2001;136:1115-1117.
5. Hallett M. One man's poison—clinical applications of botulinum toxin. *N Engl J Med.* 1999;341:118-120.
6. Kreyden OP, Schmid-Grendelmeier P, Burg G. Idiopathic localized unilateral hyperhidrosis: case report of successful treatment with botulinum toxin A and review of the literature. *Arch Dermatol.* 2001;137:1622-1625.
7. Naumann M, Lowe NJ. Botulinum toxin type A in treatment of bilateral primary axillary hyperhidrosis: randomised, parallel group, double blind, placebo controlled trial. *BMJ.* 2001;323:596-599.